

# Familial Adenomatous Polyposis Syndrome

*Mene Sugage Zua, MD*

**F**amilial adenomatous polyposis (FAP) syndrome is an autosomal dominant disease that results from mutation in the adenomatous polyposis coli (APC) gene located on chromosome 5q21-22. One third of all cases of FAP have no family history of FAP, and these cases are thought to be caused by a new germ-line mutation. The diagnosis of FAP is based on the detection of more than 100 adenomatous colorectal polyps. This article discusses a case of FAP in a 37-year-old woman with no history of colorectal cancer or polyps.

### CASE PRESENTATION

A 37-year-old woman initially presents to a primary care physician with recurrent hematochezia and constipation. She is diagnosed with hemorrhoids and treated with laxatives (oral bisacodyl, 100 mg/day) and a sitz bath at bedtime.

Approximately 6 months after the patient's initial presentation, she returns to her primary care physician with complaints of abdominal pain in the right upper quadrant. The pain is sharp, sometimes radiates to her back, and is associated with fatigue. The patient also has persistent hematochezia.

### Family History and Physical Examination

The patient has no family history of colorectal cancer or polyps. Physical examination reveals no pallor, a blood pressure of 113/72 mm Hg, and a pulse of 85 bpm. The patient is afebrile. No pigmentation, osteoma, lipoma, or cyst is noted. Results of ophthalmologic examination are normal. The patient's abdomen is tender in the right upper quadrant, extending to the epigastric region. The liver has a span of 13 cm and is tender, and nodules are appreciated. No other mass lesions are palpated, and no ascites or rebound tenderness is demonstrated.

### Laboratory and Radiographic Studies

A screening blood count and liver profile show elevated aspartate aminotransferase levels, which necessitate screening for hepatitis. The hepatitis profile is pos-

itive for hepatitis C antibody, and the patient is referred to a gastroenterology clinic. Results of laboratory examination include the following values:

- Hematocrit, 43% (normal, 40% to 48%)
- Albumin level, 3.6 g/dL (normal, 3.5 to 5.5g/dL)
- Total serum bilirubin concentration, 0.7 mg/dL (normal, 0.3 to 1 mg/dL)
- Alanine aminotransferase level, 21 U/L (normal, 10 to 40 U/L)
- Serum alkaline phosphatase level, 275 U/L (normal, 30 to 85 U/L)

Prothrombin and partial prothrombin times are normal. Electrolyte levels are normal. The alpha-fetoprotein value is 3.4 ng/mL, and the carcinoembryonic antigen value is 18 ng/mL. Ultrasonography of the abdomen shows multiple liver nodules (**Figure 1**), and biopsy shows adenocarcinoma.

### Colonoscopy and Biopsy

Colonoscopy is performed and shows multiple (more than 100) polyps in the colon extending from the rectum (**Figure 2**). The actual number of the polyps cannot be determined during the colonoscopy because hundreds of polyps span the colon and the patient has a high intolerance for pain caused by the procedure. A rectal mass is also appreciated (**Figure 3**). Biopsies of the polyps and rectal mass are consistent with tubular adenoma and adenocarcinoma (**Figure 4**). The patient is diagnosed with FAP.

### Treatment

The patient is referred to surgery and subsequently undergoes a resection of the rectal carcinoma for tumor removal and obstructive symptoms. Multiple colonic polyps are also confirmed at surgery. The patient does well

---

*Dr. Zua is a Fellow in Gastroenterology, Department of Medicine, Division of Gastroenterology, University of Tennessee at Memphis, Memphis, TN.*

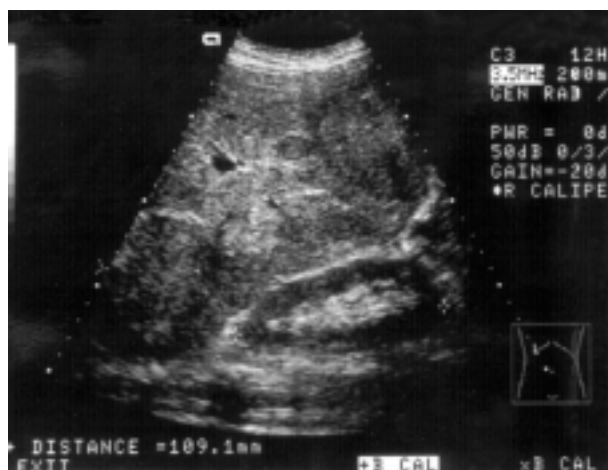

Figure 1. Abdominal ultrasound showing multiple liver masses.

postoperatively with minimal obstructive symptoms. The patient's family members are contacted for screening.

#### Subsequent Presentation

Approximately 2 months after surgery, the patient presents with new-onset seizures and mental status change, for which she is treated with phenytoin and intravenous steroids. Computed tomography and magnetic resonance imaging scans of the head demonstrate a 3.5-cm by 3-cm mass at its widest diameter and peritumoral edema in the parietal occipital cortex. The patient undergoes craniotomy for removal of the mass and does well postoperatively. The patient is currently in hospice care with do-not-resuscitate status.

#### DISCUSSION

FAP is an autosomal dominant disease characterized by the presence of hundreds to thousands of adenomatous polyps with malignant potential. Intestinal polyposis was first documented in 1861, and the hereditary nature of the disease was recognized in 1882. The pattern of transmission of the disease was published in 1887.<sup>1</sup>

#### Epidemiology

FAP and variants of this gene arise from the APC gene on chromosome 5. The FAP gene has 80% to 100% penetrance and a prevalence of approximately 0.01% in the United States.<sup>2</sup> Males and females are equally affected, and new mutations are thought to occur in approximately one third of new cases of FAP.<sup>3</sup> The prevalence of FAP is approximately one in 10,000 births and accounts for less than 0.5% of cases of colon cancer. These polyps occur in younger patients, usually at an average age of 16 years. Almost all patients

who carry the FAP gene develop polyps by age 35 years, and approximately 7% of these patients develop colon cancer by age 21 years.<sup>4</sup> For these reasons, physicians should be highly suspicious of FAP in a patient with any colonic malignancy that occurs at an early age.

#### Genetic Factors

The FAP or APC gene is located on chromosome 5q21-22. Apoptosis is the normal function of the APC protein produced by the APC gene. The mechanism of normal apoptosis involves the binding of APC gene protein with cytosolic nucleic  $\beta$ -catenin protein, which is a protein involved in cell adhesion, signaling, and proliferation. The binding of the APC gene protein to  $\beta$ -catenin causes phosphorylation and degradation of the  $\beta$ -catenin.

The mutations that occur in FAP and its variants lead to the formation of a stop codon, thereby producing an abnormal protein that is thought to inactivate the protein from the normal allele.<sup>5</sup> The formation of the stop codon causes uncoupling of  $\beta$ -catenin from the APC gene protein and results in the accumulation of  $\beta$ -catenin in the cell. The free  $\beta$ -catenin binds to nuclear proteins and causes cell proliferation and activation of transcription factor 4. Variants of FAP correlate to the point of mutation of the APC gene, and mutation of the extremes of the gene leads to attenuated APC. Expression of the gene is found in other organs, and its mutation causes carcinoma in these organs (eg, pancreatic cancer).<sup>6</sup> The APC gene mutation has been found in nonfamilial type adenomas and colon cancers. These mutations are thought to be acquired, and, in some cases, the alleles are lost;<sup>7</sup> these mutations are usually the earliest genetic alteration in cancer formation. However, a mutation can occur with an increased risk of colon carcinoma and without polyposis, as reported in approximately 6% of the Ashkenazi Jewish population.<sup>8</sup>

#### Clinical Manifestations

FAP is associated with gastric and small intestinal polyp formation, but the malignant potential of the gastric fundal polyp is low and most gastric fundal polyps are hyperplastic. The prevalence of gallbladder, bile duct, thyroid-adrenal, hepatoblastoma, and pancreatic cancer is increased in patients with FAP.<sup>4</sup> The patient in this case report did not show any symptoms of extracolonic malignancy.

Fundal polyps may comprise approximately 30% to 100% of upper gastrointestinal polyps in FAP.<sup>9,10</sup> These polyps may appear in patients at a younger age, may subsequently decrease or increase in number, and, in

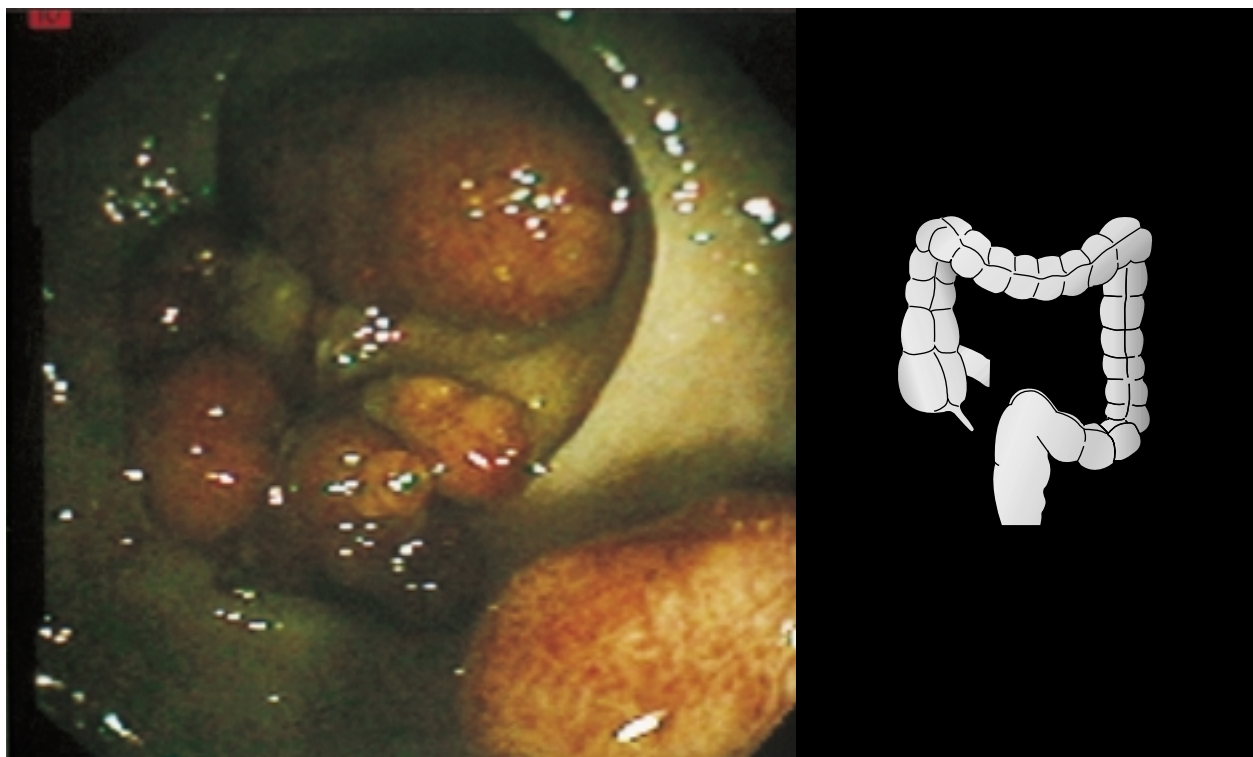


Figure 2. Polyps of various sizes detected during colonoscopy.

most cases, are nonneoplastic.<sup>10</sup> Duodenal polyps comprise 46% to 93% of upper gastrointestinal polyps in FAP, are usually multiple, and may undergo malignant change. The presence of polyps at the duodenal papilla carries an increased risk of malignant change and can lead to obstructive symptoms.

#### Colorectal Cancer

Colon malignancy is common in the United States and could be associated with new mutations as well as with inheritance; however, only a small number of mutations can be linked to known syndromes. The lifetime risk for colon cancer in males and females in the United States is approximately 6%. The presence of a first-degree relative with colon cancer or adenomatous polyps increases the risk for other family members by twofold to threefold and is even higher if the cancer occurs in the relative before age 50 years.<sup>11</sup> The presence of second- or third-degree relatives with colon cancer increases the risk by approximately 50%.<sup>12</sup> Familial susceptibility of colonic malignancy has been linked to gene polymorphisms.

#### Differential Diagnosis

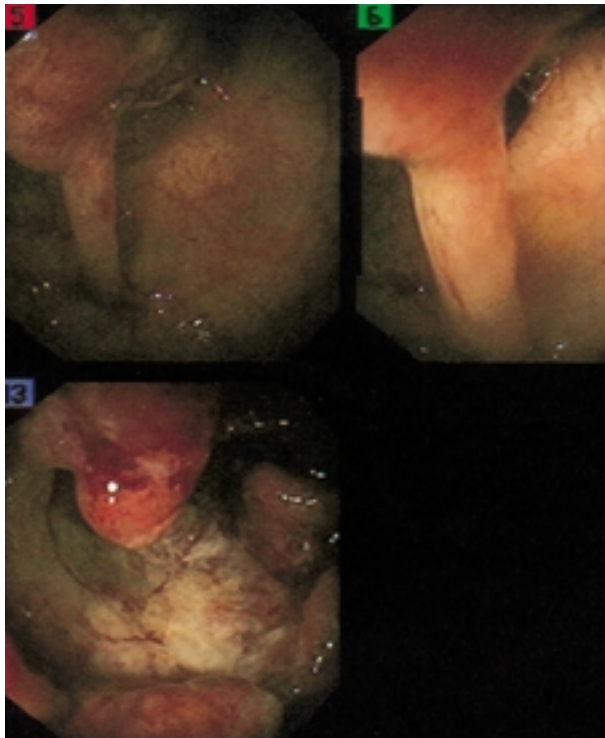
FAP syndrome must be differentiated from other

polyposis syndromes. Clinical features and histology are the key to diagnosis.

**Variants of familial adenomatous polyposis.** Variants of FAP include Gardner's syndrome, Turcot's syndrome, and attenuated adenomatous polyposis.

*Gardner's syndrome.* Gardner's syndrome is an autosomal dominant form of adenomatous polyp. The risk of cancer following diagnosis with this syndrome is approximately 100%. Gardner's syndrome usually includes features of FAP and desmoid tumor, osteoma, fibroma, dental abnormalities, and congenital hypertrophy of the retinal pigment epithelium. The histology of Gardner's syndrome is the same as that for FAP adenoma.

*Turcot's syndrome.* Turcot's syndrome is a hereditary disease in which colonic adenomatous polyps are associated with primary brain tumors, especially gliomas, glioblastomas, and astrocytomas. This syndrome usually occurs in the first and second decades of life.<sup>12</sup> The phenotypic expression of the disease can vary based on the type of brain tumor and the genetic alteration. The most common type is the mutation of the APC gene with subsequent development of medulloblastoma. The second type involves the mutation of the DNA base mismatch repair genes with formation of glioblastoma multiforme tumors.

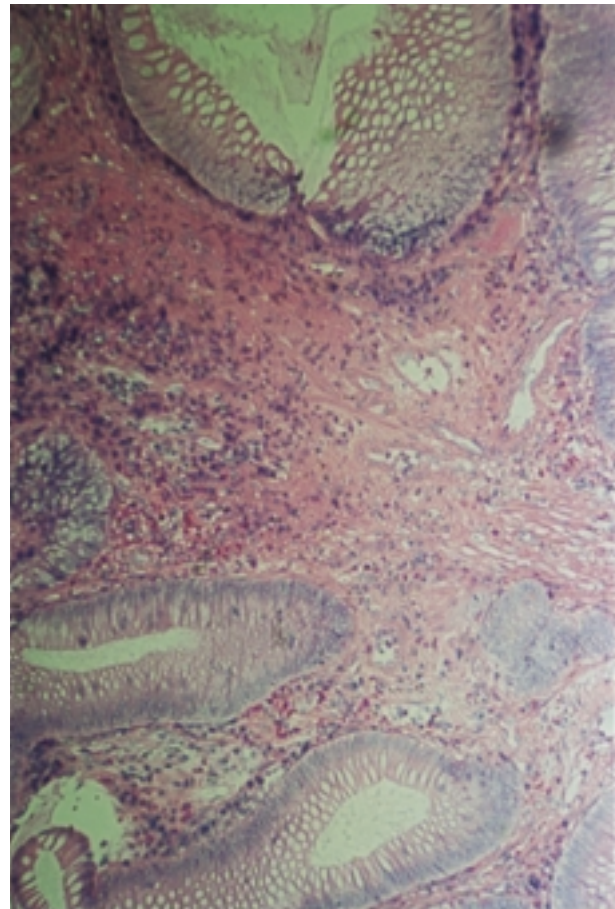


**Figure 3.** Rectal mass in the sigmoid colon detected during colonoscopy (later found to be adenocarcinoma).

*Attenuated adenomatous polyposis.* Of the variants of FAP, attenuated adenomatous polyposis presents with the most adenomas in the proximal colon. In this variant, the mutation of the APC gene occurs at the 5' end proximal portion.<sup>13</sup> In addition to clinical features, the key to diagnosis of attenuated adenomatous polyposis is the age of disease onset. The mean age of diagnosis for attenuated adenomatous polyposis is approximately 55 years, a later age compared with FAP. In addition, patients with attenuated adenomatous polyposis develop fundic, duodenal, and periampullary tumors.<sup>14</sup>

**Hamartomatous polyposis syndromes.** Hamartomatous polyposis syndromes include Peutz-Jeghers syndrome, familial juvenile polyposis coli, Cowden's syndrome, and Ruvalcaba-Myhre-Smith syndrome.

*Peutz-Jeghers syndrome.* Peutz-Jeghers syndrome is an autosomal dominant disorder. Patients with this syndrome present with mucocutaneous pigmented spots and hamartomatous polyps that occur mostly in the small intestine and stomach. This syndrome has a 3% to 6% malignancy potential and is associated with extraintestinal malignancy such as breast, cervical, ovarian, or testicular tumors. Histologically, the syndrome contains arborizing and branching muscularis



**Figure 4.** Poorly differentiated adenocarcinoma obtained from a biopsy of the site shown in Figure 2.

with mucin-producing glands. The gene for this condition has recently been mapped to chromosome 19p13, which involves mutation of the gene encoding a serine threonine kinase.<sup>15</sup> Screening should be directed to the organs at risk for malignancy.<sup>16</sup>

*Juvenile polyposis coli.* Juvenile polyposis coli occurs in the colon and carries a cancer risk of approximately 23%.<sup>17</sup> Patients usually develop the symptoms of juvenile polyposis coli between the ages of 4 to 15 years. Microscopically, the juvenile polyp contains mucous-filled cystic spaces.

Juvenile polyposis coli occurs in less than one in 100,000 live births and is autosomal dominant with high penetrance. Cytogenetic analysis indicates that the mutation for juvenile polyposis coli is on chromosome 10 and chromosome 18q21.<sup>18</sup> The mutation on chromosome 18q21 is thought to encode for a cytoplasmic mediator that is involved in the transforming growth factor- $\beta$  signaling pathway, whereas

chromosome 10 is linked to the production of phosphatase, as seen in normal apoptosis.

In familial juvenile polyposis coli, 10 or more juvenile polyps must occur. Juvenile polyposis coli is familial in one third of cases. The nonfamilial form of disease is isolated, contains less than 10 juvenile hamartomatous polyps, and is not thought to be associated with an increased cancer risk compared with the general population. However, nonfamilial juvenile polyposis coli is associated with congenital malformations such as hydrocephalus, cardiac lesion, Meckel's diverticulum, and mesentery lymphangioma.

**Cowden's syndrome.** Cowden's syndrome is characterized by multiple hamartomatous polyps of the gastrointestinal tract, skin, and mucous membrane. This syndrome is inherited in an autosomal dominant pattern. The polyps associated with Cowden's syndrome may involve the entire gastrointestinal tract. The hallmark of this syndrome is the presence of multiple facial trichilemmomas. The syndrome may be associated with café-au-lait spots, vitiligo, cysts, squamous and basal cell carcinoma, breast lesions, hemangiomas, lipomas, lymphangiomas, neurofibroma, and congenital hypoplastic mandibular prominence.

**Ruvalcaba-Myhre-Smith syndrome.** The syndrome of hamartomatous intestinal polyps that is associated with macrocephaly is Ruvalcaba-Myhre-Smith syndrome. Intussusception and Hashimoto's thyroiditis are occasional complications of this syndrome.<sup>19</sup>

**Hereditary nonpolyposis syndrome.** Type I hereditary nonpolyposis colorectal cancer (HNPCC) or Lynch syndrome type I has an autosomal dominant inheritance pattern and approximately 70% to 80% penetrance. Antecedent polyposis is absent in this syndrome. Multiple synchronous primary tumors occur in 18% of cases, and 3% to 5% of metachronous tumors develop with predilection to the proximal colon. The mutation associated with this syndrome occurs on chromosome 2.

Lynch syndrome type II is associated with adenocarcinoma of the endometrium, ovaries, stomach, small intestine, and renal pelvis. Torre's syndrome, which is characterized by multiple sebaceous gland neoplasm and colorectal cancer, is a subset of Lynch syndrome type II. The criteria for diagnosis of Lynch syndrome type II are based on the International Collaboration Group meeting in Amsterdam in 1990 and are termed the *ICG Criteria or Amsterdam Criteria* (Table 1).

Lynch syndrome is caused by mutation of the repair gene. Four genes have proteins that participate in a DNA repair process termed *mismatch repair*.<sup>20,21</sup> The DNA mismatch repair process maintains the fidelity of

**Table 1.** ICG or Amsterdam Criteria for Hereditary Nonpolyposis Colorectal Cancer Type II

---

One family member diagnosed with colorectal cancer before age 50 years
Two generations affected by the disorder
Three affected relatives; one relative must be a first-degree relative of the other two family members

---

ICG = International Collaboration Group.

DNA during replication by repairing DNA errors. The mutated mismatch repair genes produce proteins that cannot repair DNA errors or mismatches, thus leading to cancer formation. Colonic tumors from patients with Lynch syndrome exhibit many mismatches, proteins that are not repaired; these proteins are termed *RER+*. Detection of the *RER+* proteins forms the basis of gene testing in HNPCC. The mutated genes include hMSH2 located on the short arm of chromosome 2,20; hMLH1 on the short arm of chromosome 3; and hPMS1 and hPMS2 on the long arm of chromosome 2 and short arm of chromosome 7. Both MSH2 and MLH1 genes account for approximately 90% of the mismatch repair genes. *RER+* proteins also occur in approximately 15% of sporadic tumors.

HNPCC has also been linked to BAX gene mutation, which has been linked to apoptosis, although more studies are needed to confirm the HNPCC-BAX link.<sup>22</sup> The histology of HNPCC is identical to sporadic adenoma, but HNPCC occurs at a younger age.<sup>23</sup> HNPCC could be associated with other malignancies such as uterine, ovarian, renal, pancreatic, gastric, and small intestinal malignancy.

**Nonfamilial gastrointestinal polyposis.** The Cronkhite-Canada syndrome is a good example of nonfamilial gastrointestinal polyposis. This syndrome is characterized by intestinal polyposis, nail dystrophy, alopecia, skin hyperpigmentation, protein-losing enteropathy, diarrhea, weight loss, and malnutrition. The cause of Cronkhite-Canada syndrome is unknown, and the mean age of occurrence is 55 years. The polyps in this syndrome appear similar to those in juvenile polyposis, but, in contrast, inflammatory changes between the polyps are noted in Cronkhite-Canada syndrome. Other examples of nonfamilial gastrointestinal polyposis are nodular lymphoid hyperplasia and hyperplastic polyposis.

#### Diagnosis

**Clinical characteristics.** The diagnosis of FAP is established by the presence of 100 or more colonic

adenomatous polyps in patients with a partially expressed phenotype and approximately 1000 to 5000 polyps in patients with a fully expressed phenotype. Polyposis usually develops in the second or the third decade of life, although a younger age has been shown. The patient in this case study had multiple polyps at age 37 years. Two patterns of colonic polyp formation have been described—the carpeting pattern and the discrete pattern. The patient in this case study had groups of polyps that were separated by normal mucosa, which corresponds to the discrete pattern. An explanation for the heterogeneity in phenotypic pattern is unknown; however, mutation in the middle portion of the APC gene has been found to produce more than 5000 polyps in the colon, and patients with 2000 or fewer polyps have mutations proximal or distal to the middle portion.<sup>24</sup> The patient in this case study had no skin lesions or any abnormality to indicate a diagnosis of a variant of FAP.

Patients with FAP are usually asymptomatic until cancer develops or the polyps ulcerate or become large enough to cause obstructive symptoms as shown in Figures 1 and 2. Patients may present with symptoms of rectal bleeding, diarrhea, and abdominal pain and the average age of onset is 35 years.<sup>4</sup> The patient in this case study presented with rectal bleeding of long duration and later with constipation and abdominal pain. Therefore, it is prudent to aggressively evaluate a young patient who presents with intermittent rectal bleeding in the absence of hemorrhoids. The question of whether intermittent rectal bleeding is the initial presentation of FAP requires further study. Polyps in the upper gastrointestinal tract may also remain asymptomatic, and polyps at the duodenal papilla may cause obstructive jaundice or pancreatitis.<sup>24</sup> The polyps in FAP may be sessile or pedunculated, adenomatous, or villous adenoma. Histologically, the patient in this case study demonstrated adenomatous polyps on the biopsy specimen.

**Genetic testing.** Commonly available genetic testing for FAP is an *in vitro* protein synthesis test using peripheral blood. This test involves the use of DNA and DNA linkage markers to the APC gene. The test detects abnormal protein produced by the APC mutation and involves obtaining DNA from peripheral blood and *in vitro* synthesis of protein from the APC gene. The finding of truncated protein indicates mutation. This test can diagnose more than 95% of persons at risk with more than 98% accuracy; however, other forms of mutation can occur in 10% to 20% of families with FAP. The index case is tested first, and, if positive, family screening is then performed. If the restriction

fragment length analysis is not possible because of small family size or if a spontaneous mutation is suspected, then a direct molecular analysis of the APC gene mutation is advisable.

**Hereditary nonpolyposis syndrome.** Genetic evaluation for hereditary nonpolyposis syndrome is based on the same principles as those for FAP. This evaluation involves the analysis of colorectal cancer DNA for microsatellite instability or replication error (RER) phenotyping. Cancers from HNPCC show repeat sequences of bases (microsatellites) throughout the genome that are RER<sup>+</sup>. Tumor DNA that shows this phenomenon usually indicates defects in germline mismatch repair genes and a diagnosis of HNPCC. Several genes, however, must be evaluated to increase the yield of the test because the test can identify approximately 50% of families who meet the Amsterdam criteria and approximately 8% of families who have HNPCC but do not meet the Amsterdam criteria.

#### Screening

The effectiveness of screening for FAP is well established<sup>25</sup> and should be performed for the following types of patients:

- Children of affected parents
- Members of extended family who are at risk
- Patients with suspected hereditary colorectal cancer (confirmation diagnosis)

Yearly screening should begin at age 10 to 12 years, and if the patient tests negative for polyps, repeat screening can be performed every 3 years. If the initial screening is positive for polyps, then repeat screening every 1 to 2 years should be performed until the patient reaches age 35 to 40 years, after which, if test results are persistently negative, a repeat screening can be performed every 3 years. Sigmoidoscopy is often adequate because adenoma is distributed evenly throughout the colon. Upper gastrointestinal screening with side-viewing endoscopy should be performed if colonic polyps are detected.

**Type 1 hereditary nonpolyposis colorectal cancer.** In HNPCC, colonoscopy should be performed every 2 to 3 years for patients age 20 to 25 years or 10 years earlier than the age of the index patient until patients are age 70 to 75 years. Colonoscopy should be used instead of sigmoidoscopy because most adenomas occur proximal to the splenic flexure. Gynecologic screening should also be performed for female patients. Genetic testing should be offered to families in situations in which the index case is positive for

mutation. Patients who test positive should be screened as noted previously, and patients who test negative should undergo the general population cancer screening. Colonoscopy should be performed at age 20 years for patients in families with attenuated adenomatous polyposis. Screening in Turcot's syndrome should include adequate imaging studies of the brain.

**Juvenile polyposis coli.** Screening for juvenile polyposis coli is controversial, but screening could be performed in asymptomatic first-degree relatives and may involve annual blood testing and sigmoidoscopy or colonoscopy at age 12 years for every 3 to 5 years until the patients are age 40 years. Symptomatic patients are evaluated independent of age. Evaluation of these patients involves annual or biannual colonoscopy with side-viewing upper endoscopy and small bowel radiography.

#### Treatment

Surgery is the main therapy for patients with FAP. In the patient in this case study, the advanced stage of the disease at the time of diagnosis necessitated only palliative therapy for symptoms, and the patient underwent low anterior resection to alleviate obstructive symptoms. In patients with FAP and the diagnosis of adenoma, colectomy should be performed. In patients with HNPCC, a partial colectomy may be performed if cancer or advanced adenoma is detected.

There is no consensus regarding the role of medical therapy for FAP; however, medical therapy for FAP has been investigated since the discovery that a spontaneous regression of rectal polyps occurred after medical therapy. The use of vitamins C and E and supplemental fiber has been tried with modest result. The use of nonsteroidal anti-inflammatory drugs, especially sulindac, has been shown to decrease the number and size of colorectal adenoma in patients with FAP by inhibiting cyclooxygenase (COX). Colorectal tumors have a high level of COX-2 expression, rather than COX-1, compared with normal colonocytes, and inhibition of COX-2 is thought to be responsible for tumor regression. Whether to treat patients with HNPCC with screening polypectomy or prophylactic colectomy is still controversial. HP

#### REFERENCES

1. Gardner EJ, Burt RW, Freston JW: Gastrointestinal polyposis: syndromes and genetic mechanisms. *West J Med* 1980;132:488-499.
2. Smith RG: Southwestern internal medicine conference: hereditary predisposition to colorectal cancer: new insights. *Am J Med Sci* 1994;308:295-308.
3. Powell SM, Petersen GM, Krush AJ, et al: Molecular diagnosis of familial adenomatous polyposis. *N Engl J Med* 1993;329:1982-1987.
4. Burt RW: Inherited colorectal cancer syndrome: clinical update. *American Society for Gastrointestinal Endoscopy Clinical Update* 1998;5:1-4.
5. Smith KJ, Johnson KA, Bryan TM, et al: The APC gene product in normal and tumor cells. *Proc Natl Acad Sci USA* 1993;90:2846-2850.
6. Neuman WL, Wasylshyn ML, Jacoby R, et al: Evidence for a common molecular pathogenesis in colorectal, gastric, and pancreatic cancer. *Genes Chromosomes Cancer* 1991;3:468-473.
7. Reale MA, Fearon ER: Molecular genetics of hereditary colorectal cancer. *Hematology/Oncology Annals* 1994;2:129-140.
8. Laken SJ, Petersen GM, Gruber SB, et al: Familial colorectal cancer in Ashkenazim due to a hypermutable tract in APC. *Nat Genet* 1997;17:79-83.
9. Watson P, Lynch HT: Extracolonic cancer in hereditary nonpolyposis colorectal cancer. *Cancer* 1993;71:677-685.
10. Winawer SJ, Zauber AG, Gerdes H, et al: Risk of colorectal cancer in the families of patients with adenomatous polyps. National Polyp Study Workgroup. *N Engl J Med* 1996;334:82-87.
11. Slattery ML, Kerber RA: Family history of cancer and colon cancer risk: the Utah Population Database. *J Natl Cancer Inst* 1994;86:1618-1626.
12. Hamilton SR, Liu B, Parsons RE: The molecular basis of Turcot's syndrome. *N Engl J Med* 1995;332:839-847.
13. Spirio L, Olschwang S, Groden J, et al: Alleles of the APC gene: an attenuated form of familial polyposis. *Cell* 1993;75:951-957.
14. Lynch HT, Smyrk TC, Lanspa SJ, et al: Upper gastrointestinal manifestations in families with hereditary flat adenoma syndrome. *Cancer* 1993;71:2709-2714.
15. Jenne DE, Reimann H, Nezu J, et al: Peutz-Jeghers syndrome is caused by mutations in a novel serine threonine kinase. *Nat Genet* 1998;18:38-43.
16. Rebsdorf Pedersen I, Hartvigsen A, Fischer Hansen B, et al: Management of Peutz-Jeghers syndrome. Experience with patients from the Danish Polyposis Register. *Int J Colorectal Dis* 1994;9:177-179.
17. Sassatelli R, Bertoni G, Serra L, et al: Generalized juvenile polyposis with mixed pattern and gastric cancer. *Gastroenterology* 1993;104:910-915.
18. Howe JR, Roth S, Ringold JC, et al: Mutations in the SMAD4/DPC4 gene in juvenile polyposis. *Science* 1998;280:1086-1088.
19. DiLiberti JH, Weleber RG, Budden S: Ruvalcaba-Myhre-Smith syndrome: a case with probable autosomal-dominant inheritance and additional manifestations. *Am J Med Genet* 1983;15:491-495.
20. Koreth J, O'Leary JJ, O'D McGee J: Microsatellites and PCR genomic analysis. *J Pathol* 1996;178:239-248.
21. Peltomaki P, Lothe RA, Aaltonen LA, et al: Microsatellite instability is associated with tumors that characterize the hereditary non-polyposis colorectal carcinoma syndrome. *Cancer Res* 1993;53:5853-5855.

22. Yagi OK, Akiyama Y68, Nomizu T, et al: Proapoptotic gene BAX is frequently mutated in hereditary nonpolyposis colorectal cancers but not in adenomas. *Gastroenterology* 1998;114:268-274.
23. Jass JR, Smyrk TC, Stewart SM, et al: Pathology of hereditary non-polyposis colorectal cancer. *Anticancer Res* 1994;14:1631-1634.
24. Nagase H, Miyoshi Y, Horii A, et al: Correlation between the location of germ-line mutations in the APC gene and the number of colorectal polyps in familial adenomatous polyposis patients. *Cancer Res* 1992;52: 4055-4057.
25. Rhodes M, Bradburn DM: Overview of screening and management of familial adenomatous polyposis. *Gut* 1992;33:125-131.

Copyright 1999 by Turner White Communications Inc., Wayne, PA. All rights reserved.