

Series Editor: Bryan A. Liang, MD, PhD, JD

## Celiac Disease: Diagnosis and Management

Case Study and Commentary: Conor G. Loftus, MD, and Joseph A. Murray, MD

### DR. LIANG:

Celiac disease, also known as *gluten-sensitive enteropathy*, *nontropical sprue*, and *celiac sprue*, describes a pathophysiologic state in which patients are intolerant of certain amino acid sequences found in the prolamins of wheat, rye, and barley (gliadin, secalin, and hordein, respectively).<sup>1</sup> As such, the disease results in immunologically mediated lesions of the small intestines and subsequent malabsorption because of a toxic reaction.<sup>2</sup>

As noted in this case study, the incidence of the disease is much higher than once thought, even in countries where it was originally considered rare, including the United States.<sup>3,4</sup> The disease is the most common genetic disease among Europeans,<sup>5</sup> and thus persons in North America of European ancestry may be susceptible to celiac disease. Given its common nature and the debilitating morbidity, mortality, and possible severe complications (eg, osteoporosis, lymphoma, anemia) associated with the disease, primary care physicians must maintain a high index of suspicion for the disorder in patients whose initial symptoms include gastrointestinal disturbances and chronic diarrhea.<sup>6</sup> Unfortunately, many patients first present with atypical celiac disease, which can result in the disease being undiagnosed or misdiagnosed in as many as 60% of cases.<sup>7</sup>

Although treatment for celiac disease rests squarely on prescribing a gluten-free diet, there is significant variation regarding what such a diet actually comprises and whether a diet is truly free of glutens. In the United States and Canada, gluten-free diets are entirely free of glutens and other prolamins toxic to patients with celiac disease; the focus in these countries is on the use of foods that are naturally free of glutens, such as rice and corn.<sup>8</sup> However, in Europe (eg, the United Kingdom, Scandinavian countries) and in Australia, a standard gluten-free diet can include foodstuffs that use wheat starch containing small amounts of toxic prolamins.<sup>9,10</sup> This variation and the debate it has generated largely results from the fact that the quantity of gliadin and other prolamins known to be toxic to patients with celiac disease that may be ingested without

damaging the mucosa of the small intestine is unknown. Thus, a spectrum of opinions—from zero tolerance of gliadin and similar prolamins<sup>11</sup> through allowances for small amounts occurring in so-called gluten-free wheat starch and other foods<sup>9</sup>—exists in the literature.<sup>12</sup>

In light of the importance of knowing the amount of gluten in foods available to patients with celiac disease, international standards have been developed to guide patients and health care providers. The Codex Standard for Gluten-Free Food was developed by the Codex Alimentarius Commission, a program of the World Health Organization and the Food and Agricultural Organization of the United Nations.<sup>13</sup> Under this standard, gluten-free foods may contain wheat, rye, barley, oats, and triticale that have been rendered gluten-free. Under Codex, gluten-free is defined using nitrogen content: the nitrogen content of grain containing gluten must be less than or equal to 0.05 g per 100 g of grain (on a dry matter basis); indirect use of nitrogen reflects the lack of a methodology to directly measure gluten content at the time the standard was developed.<sup>14</sup>

The Codex standard for gluten-free foodstuffs is in the process of redefinition under the Draft Revised Standard for Gluten-Free Foods.<sup>15,16</sup> Under the new standard, naturally occurring gluten-free foods may contain no more than 20 ppm of gluten to be deemed gluten-free. Foodstuffs (including those containing wheat, rye, and barley) from which gluten and other prolamins have been removed may not contain more than 200 ppm of gluten to be considered gluten-free. It should be noted that other ingested materials—such as medications—must also be scrutinized for gluten content, because some of the agents contained therein may

---

*Drs. Loftus and Murray are from the Division of Gastroenterology and Hepatology, Mayo Clinic, Rochester, MN. Dr. Liang is a Professor of Health Law & Policy, University of Houston Law Center, Houston, TX; a Professor of Medical Humanities, University of Texas Medical Branch, Galveston, TX; and a member of the Hospital Physician Editorial Board.*

contain gluten and other toxic prolamins.<sup>17</sup> These associated issues with prolamins should underscore for the primary care physician the importance of gluten-free nutrition in patients with celiac disease but should not mask the need for nutritional supplementation, because many gluten-free diets using refined flours and/or starch are not enriched with iron and B vitamins.<sup>18</sup>

Furthermore, as noted in this case study, celiac disease is associated with an increased incidence of mortality overall as well as a higher mortality in adult patients with cancer.<sup>19</sup> Indeed, some reports have indicated a 1.9- to 3.4-fold increase in mortality in these patients,<sup>20</sup> although these estimates may be artificially high because of the confounding effects of including in these estimates patients with anticipated poorer outcomes (eg, patients with refractory sprue, patients with intestinal lymphoma).<sup>21</sup> In addition, directly related to the finding of higher mortality in patients with celiac disease is the specter of a higher mortality in relatives of patients with the disease; there is significant debate as to whether direct relatives of celiac disease patients do<sup>22</sup> or do not<sup>23</sup> have an increased likelihood of developing and dying from malignancies. More research is required to further investigate these conflicting findings.

Overall, celiac disease is a very common disorder, and primary care physicians must take an active role in diagnosing and treating affected patients. Because of the potential for misdiagnosis and the highly negative sequelae of untreated celiac disease, providers must be vigilant and maintain both an active suspicion of the presence of this disease and a low threshold for testing. Finally, once the diagnosis is made, implementation of a gluten-free diet, with the assistance of Codex and other standards, is necessary to ensure effective treatment and management of the disease.

---

#### **DRS. LOFTUS AND MURRAY:**

Until recently, celiac disease was considered uncommon in the United States, with an estimated prevalence of 1 case per 4800 persons.<sup>24</sup> With the availability of new, accurate serologic tests and a greater awareness of its presentations, celiac disease is now recognized as a much more common condition.<sup>25</sup> As many as 1 in 120 to 300 persons in both Europe<sup>26–28</sup> and North America<sup>25</sup> may have celiac disease. Many of these cases are clinically silent ones identified by screening serology or biopsy of the small intestine. In most series, there is a female preponderance. The familial prevalence of this disease is approximately 5% to 20% in first-degree family members of a patient with celiac disease.

Long-standing untreated celiac disease may be associ-

ated with the development of potentially life-threatening complications, such as enteropathy-associated T-cell lymphoma or carcinoma of the oropharynx, esophagus, and small intestine.<sup>29,30</sup> Because accurate serologic tests are now available, some have suggested that at-risk first-degree relatives and patients with diabetes mellitus should be screened for celiac disease.<sup>31,32</sup>

The increasing use of serologic testing and screening of at-risk groups will lead to further increases in the number of patients being identified with celiac disease. This article highlights the rising prevalence of both clinically silent and overt cases of celiac disease in the primary care setting and reviews important points in the diagnosis and management of celiac disease for the primary care physician.

#### **CASE STUDY**

##### **Initial Presentation**

A 35-year-old woman goes to her primary care physician reporting fatigue and shortness of breath.

##### **History and Physical Examination**

The patient had been well until 2 months prior to her presentation. At that time, she noted that she was fatigued during the day despite sleeping well at night. At first she attributed the symptom to the fact that her children were on summer vacation, but when she found that she was becoming short of breath while walking up stairs, she made the appointment to see her physician. The patient has no significant past medical history and is not taking any medications. She states that the duration and frequency of her menstrual periods are normal. Her appetite is good, she has not lost weight, and she has not experienced abdominal pain, bloating, or diarrhea.

Physical examination reveals a pale white woman who appears well nourished. Height is 148 cm (4 ft 10 in), and weight is 51 kg (112.4 lb) with a body mass index of 22.37. The abdomen is soft and nontender with no mass or hepatosplenomegaly. The remainder of the examination is also unremarkable.

##### **Laboratory Testing**

Laboratory findings include a hemoglobin level of 8.6 g/dL with a mean corpuscular volume of 67.8 fL. The ferritin level is 3 µg/L. Stools are negative for occult blood. A blood smear reveals hypochromasia and microcytosis as well as target cells and Howell-Jolly bodies (**Table 1**).

- **What are the clinical manifestations of celiac disease?**

### Clinical Presentation

Celiac disease has a wide spectrum of gastrointestinal and extraintestinal manifestations (**Table 2**). Although most cases of celiac disease are diagnosed in adulthood, age at presentation may range from 6 months to more than 85 years. Approximately 20% of cases occur in patients older than 60 years.<sup>33</sup>

Infants with celiac disease usually present between the ages of 4 and 24 months with impaired growth, diarrhea, and abdominal distension.<sup>34</sup> Symptoms begin gradually after the introduction of cereals into the diet, and a decrease in the velocity of weight gain may precede weight loss in this setting. Older children with severe untreated celiac disease may present with pubertal delay, short stature, iron deficiency anemia, or rickets. In adults, celiac disease is typically associated with symptoms of malabsorption, including diarrhea, steatorrhea, anemia, vitamin deficiency, and weight loss. However, 50% of adult patients do not have clinically significant diarrhea.

Overt evidence of malabsorption may be absent in patients with partial villous atrophy. Such patients are likely to have more atypical presentations, especially monosymptomatic presentations such as fatigue, depression, arthralgias, milk intolerance, osteomalacia or osteoporosis, and iron deficiency anemia. A very high level of clinical suspicion needs to be maintained to recognize these cases. At presentation, the case patient had a hypochromic microcytic anemia secondary to iron deficiency. This is now the most common presentation in adults with celiac disease.<sup>35</sup>

Several studies have shown that there is frequently significant delay, often measured in years, between patient presentation and the diagnosis of celiac disease.<sup>36</sup> Abdominal discomfort and bloating are common and often lead to a mistaken diagnosis of irritable bowel syndrome. A worsening of symptoms while the patient is on a high-fiber diet most likely results from the high gluten content of whole grains and should prompt the physician to consider at least the possibility of underlying celiac disease.

Celiac disease may present during pregnancy or in the postpartum period, and the diagnosis should be considered in pregnant women in whom severe anemia develops. Occasionally, celiac disease may manifest as dermatitis herpetiformis. This intensely pruritic papulovesicular eruption on the extensor surfaces is only seen in a minority of patients with celiac disease, but 70% to 80% of patients with the rash have coexisting damage in the intestine.

- **How is celiac disease diagnosed?**

**Table 1.** Laboratory Findings of the Case Patient at Presentation

Variable	Result	Reference Range
Hemoglobin, g/dL	8.6*	12.0–15.5
MCV, fL	67.8*	81.6–98.3
Leukocytes/L	$11.3 \times 10^9$	$3.5–10.5 \times 10^9$
Platelets/L	$310 \times 10^9$	$150–450 \times 10^9$
Blood smear		
Microcytes	Moderate*	
Hypochromasia	Moderate*	
Target cells	Present*	
Howell-Jolly body	Present*	
Vitamin B <sub>12</sub> , ng/L	553	200–650
Folate (serum), µg/L	11.1	> 3.5
Ferritin, µg/L	3*	20–200
Free retinol (vitamin A), µg/L	462	360–1200
α-Tocopherol (vitamin E), mg/L	11.9	5.5–17.0
25-Hydroxyvitamin D, ng/mL	18	8–38
Sodium, mEq/L	136	135–145
Potassium, mEq/L	3.9	3.6–4.8
Calcium, mg/dL	9.8	8.9–10.1
Alkaline phosphatase, U/L	183	84–218
Alanine aminotransferase, U/L	10	9–29
Creatinine, mg/dL	0.7	0.6–0.9

MCV = mean corpuscular volume.

\*Abnormal.

### Diagnostic Approach

The diagnostic tests of choice and an algorithmic approach to the diagnostic work-up of a patient with suspected celiac disease are outlined in **Table 3** and **Figure 1**, respectively. Laboratory test abnormalities, as a result of deficiency states secondary to small intestine inflammation and damage, are often the first clue to a diagnosis of celiac disease. Such deficiency states most commonly involve iron, folate, calcium, and the fat-soluble vitamins A, D, E, and K. Vitamin B<sub>12</sub> deficiency may be seen in as many as 40% of newly diagnosed cases of celiac disease.<sup>37</sup> A complete blood count and a blood smear are useful. The blood count will frequently reveal anemia with or without microcytosis. Target cells and Howell-Jolly bodies on blood smear, as found in the case patient, may suggest associated hyposplenism. Vitamin deficiencies are reflected in decreased serum levels of free retinol (vitamin A), α-tocopherol

**Table 2.** Spectrum of Clinical Presentations of Celiac Disease

Common Features	Less Common Features	Associated Conditions	Complications
<b>Adults</b>	<b>General</b>	Dermatitis herpetiformis	Refractory sprue
Iron-deficiency anemia	Short stature	IgA deficiency	Small intestine T-cell lymphoma
Diarrhea	Delayed puberty	Type I diabetes mellitus	Adenocarcinoma of oropharynx, esophagus, small intestine
Weight loss	Fatigue	Autoimmune thyroid disease	Ulcerative jejunoileitis
Steatorrhea	<b>Gastrointestinal</b>	Sjögren's syndrome	Collagenous sprue
Bloating	Recurrent aphthous stomatitis	Microscopic colitis	Ataxia
Lactose intolerance	Recurrent abdominal pain	Rheumatoid arthritis	Dementia
<b>Children</b>	Abnormal liver blood tests	Down syndrome	Benign strictures
Diarrhea	Vomiting	IgA nephropathy	Pancreatic insufficiency
Failure to thrive	Constipation		Gastroparesis
Abdominal distention	<b>Other</b>		
	Folate-deficiency anemia		
	Osteoporosis or osteopenia		
	Vitamin K deficiency (prolonged prothrombin time)		
	Thrombocytosis (hyposplenism)		
	Arthralgia, arthropathy		
	Infertility		
	Neuropathy		
	Dental enamel defects		

(vitamin E), and 25-hydroxyvitamin D. A prolonged prothrombin time due to vitamin K deficiency is very rare but should be corrected before biopsy of the small intestine is performed. Such abnormalities in isolation are nonspecific, and their cause needs to be substantiated with further testing.

The best noninvasive tests for celiac disease involve the highly sensitive and specific serologic markers, including IgA antiendomysial antibody, IgA and IgG antigliadin antibodies, and tissue transglutaminase antibody. Tests for these markers are used to evaluate patients with suspected disease, monitor adherence and response to gluten-free diet, and screen patients with possible atypical presentations.<sup>38</sup> The available serologic tests demonstrate variable sensitivity and specificity (Table 4).<sup>39–41</sup> Prior to testing, it is important that patients not reduce their gluten intake, because the antibody levels can drop rapidly. Our experience and the literature support measurement of IgA tissue transglutaminase antibody level as the most useful single serologic test for celiac disease.<sup>42</sup> Tissue transglutaminase is the autoantigen recognized by the antien-

domysial antibody. Because this test is highly specific (91% to 98%), false-positive results are rare, but false-negative results may occur in patients with mild enteropathy, children younger than 2 years, patients with selective IgA deficiency, and those with partially treated celiac disease (ie, in cases of dietary noncompliance).

Although the IgA and IgG antigliadin antibody measurements are sensitive tests, they are less specific than are both the tissue transglutaminase and the antiendomysial antibody tests.<sup>43</sup> The lower specificity may lead to frequent false-positive results in normal individuals, particularly in patients with other causes of inflammation within the gastrointestinal tract.<sup>44</sup> However, the IgA antigliadin test is particularly important in children younger than 2 years, whereas testing for the IgG antigliadin antibody is most important in the 2% to 10% of patients with coexisting celiac disease and selective IgA deficiency. In this setting, an alternative approach is to measure total IgA levels and, if these are deficient, to then measure IgG antiendomysial antibodies as a special request.

In practice, if either the endomysial or tissue

transglutaminase antibody test is positive, no further serologic testing is usually required; the diagnosis is confirmed with biopsy of the small intestine. The gold standard test for diagnosis of celiac disease is such a biopsy and subsequent histologic evaluation by an experienced pathologist. At least 3 substantial endoscopic biopsy samples should be taken from the second or third portions of the duodenum to avoid the architectural distortion caused by Brunner's glands or peptic duodenitis more proximally. Histologically, celiac disease is characterized by increased intraepithelial lymphocytes, crypt hyperplasia, increased plasma cells and lymphocytes in the lamina propria, and, in severe cases, total villous atrophy (**Figure 2**). Patients with mild focal involvement of the proximal small bowel are likely to have few overt symptoms, whereas those with extensive enteropathy may have more pronounced diarrhea, weight loss, and steatorrhea.

### Serologic Testing and Biopsy

The results of serologic testing for IgA antiendomysial, IgA antigliadin, and IgG antigliadin antibodies in the case patient are positive (**Table 5**). Tissue transglutaminase antibody testing is also positive. Esophagogastroduodenoscopy with biopsy of the small intestine confirms the presence of partial villous atrophy in association with increased intraepithelial lymphocytes and crypt hyperplasia. The physician makes a diagnosis of celiac disease.

- **What is the treatment of celiac disease?**

### Treatment

Once a diagnosis of celiac disease has been established, as with any newly diagnosed chronic disease, the initial step in management is patient education. The combined efforts of an actively interested, optimistic physician and an experienced dietitian will prove invaluable in this respect. As a means to encourage ongoing education, patients should be advised to join both local and national celiac disease support groups.

The cornerstone of treating patients with celiac disease is the gluten-free diet. The goal of the gluten-free diet is to achieve healing and maintain health through the adoption of a well-balanced, interesting dietary lifestyle that avoids gluten. In the setting of celiac disease, gluten is defined as any protein-containing derivative of the offending grains (**Table 6**). Hidden sources of gluten are frequently present in what would otherwise appear to be "safe" foods. Patients should be instructed that if they are in doubt, they should inquire whether a food has any ingredients derived from or processed with wheat, barley,

**Table 3.** Diagnostic Tests for Celiac Disease

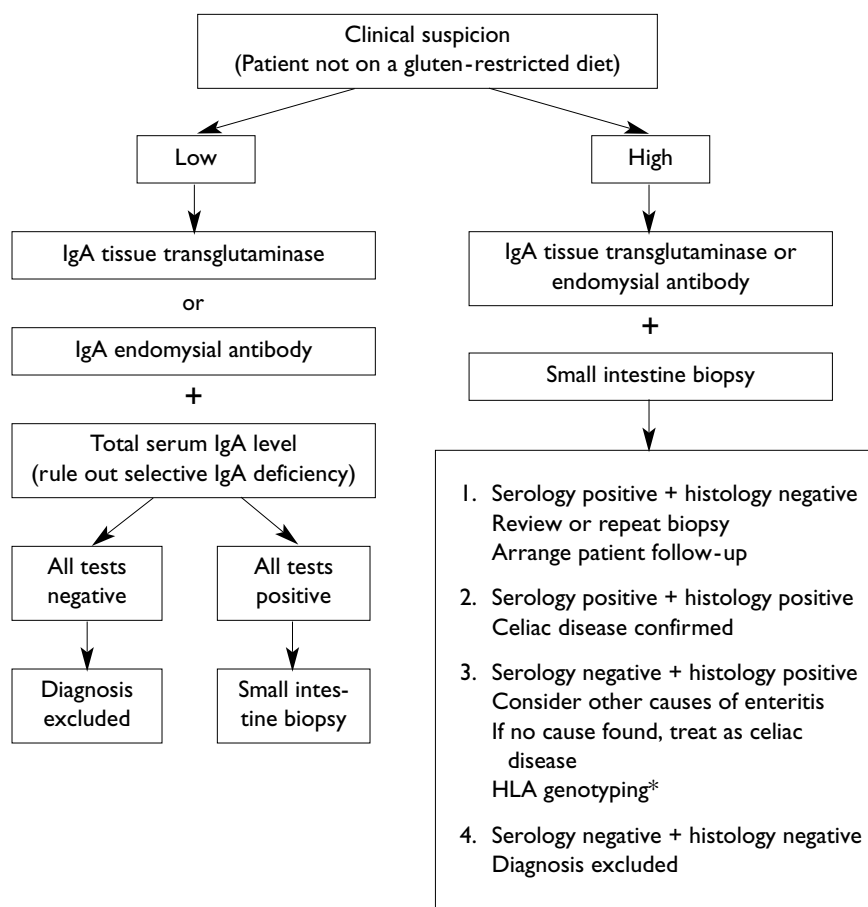
Specific Tests	Nonspecific Tests
<b>Serology</b>	<b>Laboratory tests for deficiency states</b>
Tissue transglutaminase antibody IgA	Iron, folate, vitamin B <sub>12</sub> deficiency
Endomysial antibody IgA	Hypoalbuminemia
Gliadin antibody IgA/IgG	Vitamin A, D, E, K deficiency (fat-soluble vitamins)
<b>Histology*</b>	Hypocalcemia
Normal biopsy	<b>Tests of absorption</b>
Increased intraepithelial lymphocytes	<b>Bone densitometry</b>
Decreased villous height with increased crypt depth, subtotal villous atrophy	<b>Class II HLA genotyping</b> (may help exclude patients if DQ2 or DQ8 is absent)
Total villous atrophy†	
<b>Response to gluten-free diet</b>	

\*Entries are in order of increasing severity.

†This lesion is characteristic of but not diagnostic for celiac disease. It may also be seen with severe giardiasis, tropical sprue, infantile food sensitivities, graft versus host disease, chronic ischemia of the small intestine, and Ig deficiencies.

rye, or oats. There are a number of grains that are safe in celiac disease; a sample list of foods that are safe in patients with celiac disease is provided in **Table 7**. The issue with oats is somewhat controversial, and they may in fact not be toxic to patients with celiac disease. However, because it is difficult to obtain oats that are not contaminated with gluten-containing grains, oats should be avoided in all patients with newly diagnosed celiac disease until remission is achieved on a gluten-free diet. Then, up to 2 oz per day of pure uncontaminated oats, if available, may be reintroduced to the diet if the patient has no ill effects.<sup>35</sup> Within 2 weeks of commencing a gluten-free diet, approximately 70% of patients will note symptomatic improvement.<sup>45</sup> If a patient has no response to the diet, the most common explanation is noncompliance.<sup>46</sup>

Dermatitis herpetiformis responds to suppressive medications such as dapsone, which may be required for the initial control of symptoms. However, this treatment does not lead to healing of the small intestine. In contrast, a gluten-free diet will allow most patients with dermatitis herpetiformis to discontinue the medication within 18 months and also will result in healing of the small intestine. The goal is to achieve control of the rash and maintenance on a gluten-free diet alone.



**Figure 1.** Approach to the diagnosis of celiac disease. \*Absence of alleles encoding DQ2 and DQ8 make a diagnosis of celiac disease unlikely.

**Table 4.** Serologic Tests for Untreated Celiac Disease

Test for Antibody	Sensitivity, %	Specificity, %	Cost, \$*
IgA endomysial	75–90	98–100	170
IgA tissue transG†	91–98	91–98	67
IgA antigliadin	62–100	58	61
IgG antigliadin	53–90	60–94	61

\*Costs were estimated from Medicare usual and customary fees per procedure code plus facility fee.

†IgA tissue transglutaminase.

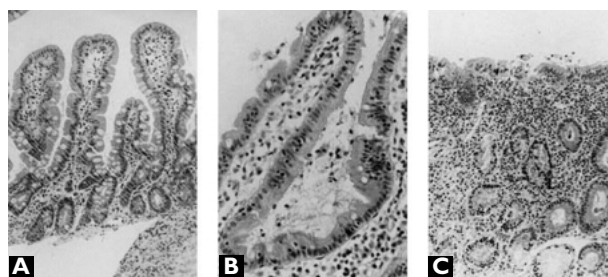
Dairy products may need to be restricted initially because patients with untreated celiac disease often have secondary lactase deficiency. After 3 to 6 months of a strict gluten-free diet, adequate mucosal healing should have occurred to allow for gradual reintroduction of dairy products.

Specific nutritional supplementation frequently will

be required in patients with celiac disease. The most common elements that are deficient are iron, folate, vitamin B<sub>12</sub>, calcium, and the fat-soluble vitamins A, D, E, and K. Bone density should be measured at the time of diagnosis to evaluate for secondary osteoporosis or osteomalacia. Adequate replacement is ensured with 1000 to 1500 mg of calcium and 400 to 800 IU of vitamin D per day in adults. Patients with osteoporosis should also be advised to get adequate daily exercise (walking or jogging 1 to 2 miles per day) and to avoid tobacco and alcohol. Consideration should be given to hormone replacement therapy in menopausal women with celiac disease. Patients with secondary hypoplenism should also receive pneumococcal vaccination and should be advised to seek prompt medical evaluation for any suspected infection.

#### Initiation of Gluten-Free Diet

The physician informs the patient of the diagnosis and advises her to begin a strict gluten-free diet. The physician explains the importance of adherence to this diet and refers the patient to a dietitian who will assist



**Figure 2.** Hematoxylin- and eosin-stained sections of small bowel mucosa demonstrating histologic changes of celiac disease. (A) Normal results from biopsy specimen of the small intestine. (B) Increased intra-epithelial lymphocytes infiltrating villi. (C) Total villous atrophy typical of celiac disease. (Adapted from Hoffenberg EJ, Bao F, Eisenbarth GS, et al. Transglutaminase antibodies in children with a genetic risk for celiac disease. *J Pediatr* 2000;137:356–60. With permission from Elsevier.)

**Table 5.** Results of Serologic Tests in the Case Patient

Variable	Result	Reference Range
Gliadin antibody IgG	71*	< 25 = negative
Gliadin antibody IgA	144.8*	< 25 = negative
Endomysial antibody IgA	Positive titer 1:40*	
Tissue transglutaminase antibody IgA	25 units	> 30 units = positive 20–30 units = weakly positive < 20 units = negative

\*Abnormal.

her with food selection. She is prescribed ferrous sulphate 325 mg twice daily in light of the iron deficiency anemia. Bone densitometry reveals significant osteopenia, so the patient is also started on elemental calcium (1500 mg daily) and vitamin D (800 IU daily). Pneumococcal vaccination is administered in light of evidence of hyposplenism.

At a follow-up visit 12 weeks later, the patient reports feeling well with no fatigue or shortness of breath. Complete blood count reveals a hemoglobin level of 12.9 g/dL with a mean corpuscular volume of 83.6 fL. Tissue transglutaminase antibody testing is repeated, and results are now found to be negative. Because the patient is doing well clinically, biopsy of the small intestine is not repeated. The importance of

**Table 6.** Sources of Gluten

**Grains**

- Wheat
- Barley
- Rye
- Oats\*
- Spelt
- Kamut
- Triticale

**Hidden ingredients**

- Contamination of foodstuffs with wheat
- Glues and pastes
- Airborne flour
- Communion wafers
- Fat replacers
- Medications: prescription and over the counter
- Beer

**Suspicious ingredients**

- Malt and malt flavoring
- Hydrolyzed vegetable protein
- Modified food starch
- Natural flavorings
- Vegetable gum (oat)
- Monoglycerides and diglycerides

\*May be reintroduced, if tolerated, when patient is in remission and gluten-free oats are available.

maintaining the gluten-free diet is again reinforced. Iron replacement therapy is discontinued. Calcium and vitamin D replacement is maintained, and a follow-up bone densitometry is scheduled to be performed 1 year after the initial scan.

• **How is the well patient with stable celiac disease managed?**

**Management in Patients with Stable Disease**

Treating the patient with chronic stable celiac disease again emphasizes the importance of maintaining dietary compliance. Periodic nutritional review and monitoring is provided on an ongoing basis by the enthusiastic physician and the experienced dietitian. A well-balanced diet is designed, with emphasis on intake of carbohydrates, protein, adequate calories, and calcium.

**Table 7.** Foods That Are Safe in Celiac Disease

---

**Meats**

Plain meat (no bread or bread crumbs)

Poultry

Fish

Shellfish

**Milk**

**Vegetables**

All fresh vegetables

Plain frozen vegetables

Vegetable juices

**Fruit**

All plain/fresh fruits

Pure fresh/canned fruit juice

**Fats and oils**

Butter

Vegetable oil

Gravy, cream, white sauces with allowed flours

**Desserts**

Gelatin

Homemade custard

Meringue

Homemade cakes (gluten-free)

**Grains**

White, brown, wild rice

Corn

Soy

Millet

Buckwheat

Specially prepared breads

Pure corn, rice cereals

**Sweets**

Sugar

Jelly, jam

Honey

---

Once a diagnosis of celiac disease has been established and a gluten-free diet instituted, the serologic markers used for diagnosis are useful for monitoring response, as well as adherence to the diet. With dietary compliance, the levels of IgA endomysial and tissue transglutaminase antibodies diminish within 6 weeks, and by 6 months both may be undetectable.<sup>47</sup> The IgG

antigliadin antibody is more persistent and may be present a year after starting gluten restriction. Serologic test results that were abnormal at diagnosis should be monitored until they are normal. Thereafter, further serologic testing is only indicated to rule out dietary noncompliance. With regard to histologic follow-up, some advocate biopsies until results are normal and then every 5 years thereafter, to monitor for continued healing.

The physician should maintain a heightened awareness for the potential development of related conditions or complications. Patients should also be educated with regard to warning symptoms and signs such as abdominal pain, weight loss, vomiting, recurrent diarrhea, and anemia; the onset of any of these should prompt further evaluation. Autoimmune diseases such as type 1 diabetes mellitus<sup>48</sup> and autoimmune thyroiditis<sup>49</sup> occur more commonly in patients with celiac disease. The prevalence of celiac disease in patients with diabetes mellitus is approximately 3% to 8%.<sup>48</sup> For this reason, consideration should be given to screening all newly diagnosed insulin-dependent diabetic patients for celiac disease using the tissue transglutaminase antibody test. The duration of gluten exposure is associated with higher prevalence of coexisting autoimmune conditions, which is an additional reason for the early diagnosis and treatment of celiac disease.<sup>50</sup>

The development of hypoalbuminemia, anemia, recurrent steatorrhea, weight loss, abdominal pain, fevers, or malaise in a previously stable patient should prompt a search for neoplasm. T-cell lymphoma of the small intestine may present either with a return of malabsorptive symptoms or as a surgical emergency with obstruction, perforation, or (rarely) bleeding. Prognosis for complicating lymphomas presenting with a surgical abdomen is better than for those presenting with insidious return of symptoms.<sup>51</sup> Malignancy is more common in patients older than 40 years. The risk for developing malignancy diminishes with the duration of dietary compliance. Adenocarcinoma of the oropharynx, esophagus, and small intestine is also seen with increased frequency in patients with celiac disease.<sup>23</sup>

Osteoporosis may develop in patients with celiac disease, particularly in those who have a delayed diagnosis or are noncompliant with a gluten-free diet. If results of bone densitometry performed at diagnosis are abnormal, a follow-up scan is recommended within 1 year. With reversal of the malabsorption state, patients may experience a rise in cholesterol levels or excessive weight gain. A lipid profile should be checked after approximately 1 year of dietary compliance.

Long-term management of patients with celiac

disease should also include a family review for symptoms of celiac disease and screening of first-degree relatives. Although screening is not generally accepted to date, increased awareness of the prevalence of the disease in association with sensitive new serologic tests may lead to its future acceptance as a means for detecting early or presymptomatic disease in family members and others at risk for celiac disease.

### Twelve Years Later

Twelve years after being diagnosed with celiac disease, the patient returns with cramping abdominal pain and weight loss. A radiographic examination of the small bowel is performed, revealing moderate dilation of the duodenum in association with an apple core-type lesion in the proximal jejunum. Computed tomography (CT) scan of the abdomen confirms the presence of a stricture in the proximal jejunum associated with marked wall-thickening suggestive of a tumor. There is no evidence of metastatic disease.

- **What is the role of imaging studies in celiac disease?**

Radiologic testing is of little use in the initial evaluation of patients with suspected celiac disease. However, small intestine contrast radiographs and CT scanning of the abdomen should be considered in patients with refractory disease and in patients with suspected complications, such as lymphoma, carcinoma, strictures, or ulcerative jejunoileitis. As occurred in the case patient, the radiographic series of the small intestine may reveal dilation of the proximal small bowel, strictures, or a mass lesion. Abdominal CT findings suggestive of celiac disease include splenic atrophy, ascites, and lymphadenopathy, whereas localized wall thickening of the small intestine may suggest the presence of lymphoma or carcinoma.<sup>52</sup>

### Further Evaluation

The patient undergoes an extended upper endoscopy, which reveals a tight stricture in the jejunum. Following dilatation of this stricture, a neoplastic mass is identified in the proximal jejunum. The patient undergoes exploratory laparotomy, resection of the involved jejunum, and end-to-end jejunojejunostomy. Pathology confirms the presence of an invasive adenocarcinoma forming a polypoid mass associated with a stricture. The resection margins are negative for malignancy, and regional lymph nodes are not involved with metastatic disease. The patient has an uneventful postoperative recovery and is discharged home on a strict gluten-free diet.

- **What is refractory celiac disease?**

### Refractory Disease

Refractory celiac disease is a diagnosis of exclusion defined by persistent symptoms of malabsorption despite a strict gluten-free diet for at least 6 months with continued villous atrophy on duodenal biopsy. Refractory disease, which affects 5% of patients with celiac disease, can be a particularly challenging problem. A detailed dietary review should be performed to determine whether the diet is fully gluten-free.<sup>46</sup> Tests for antiendomysial and antigliadin antibodies should be negative; a positive result suggests noncompliance with the dietary restrictions. Patients with refractory disease are often elderly and at high risk for development or coexistence of complications such as enteropathy-associated T-cell lymphoma, ulcerative jejunoileitis, and collagenous sprue. As many as 75% of these patients harbor an abnormal clonal intraepithelial T-lymphocyte population; it has been suggested that this condition be classified as *cryptic enteropathy-associated T-cell lymphoma*.<sup>53</sup> Patients with refractory celiac disease are frequently very ill, with marked protein-losing enteropathy, and often require total parenteral nutrition. Treatments include administration of corticosteroids and other immunosuppressive agents, such as azathioprine and cyclosporine.<sup>54,55</sup>

In patients with persistent diarrhea, one should consider the possibility of a coexisting second diagnosis. Patients with celiac disease will have had a thorough evaluation for diarrhea if it was present at the time of initial diagnosis. However, prior to making a diagnosis of refractory celiac disease, it may be necessary to reevaluate the patient for additional diagnoses, such as microscopic colitis, pancreatic exocrine insufficiency, and lactose and fructose intolerance. The possibility of alternate diagnoses should be reexamined. Whipple's disease, severe bacterial overgrowth, eosinophilic gastroenteritis, ischemic enteritis, immunodeficiency states, and amyloidosis should be considered.

### SUMMARY

Celiac disease is much more prevalent than previously recognized. Increased awareness among physicians and the availability of sensitive and specific serologic tests have led to the identification of many mild and clinically silent cases of celiac disease. These cases are frequently identified in the primary care setting, highlighting the importance of maintaining a high degree of clinical suspicion for celiac disease. **HP**

## REFERENCES

1. Thompson T. Wheat starch, gliadin, and the gluten-free diet. *J Am Diet Assoc* 2001;101:1456–9.
2. Troncone R, Greco L, Auricchio S. Gluten-sensitive enteropathy. *Pediatr Clin North Am* 1996;43:355–73.
3. Not T, Horvath K, Hill ID, et al. Celiac disease risk in the USA: high prevalence of antiendomysium antibodies in healthy blood donors. *Scand J Gastroenterol* 1998;33:494–8.
4. Catassi C, Ratsch IM, Fabiani E, et al. Coeliac disease in the year 2000: exploring the iceberg. *Lancet* 1994;343:200–3.
5. National Institutes of Health. Celiac disease. Washington (DC): US Government Printing Office; 1998. NIH Pub. No. 98-4225.
6. Dickey W, McMillan SA, Hughes DF. Identification of coeliac disease in primary care. *Scand J Gastroenterol* 1998;33:491–3.
7. Howdle PD, Losowsky MS. Coeliac disease in adults. In: Marsh MN, editor. *Coeliac disease*. Oxford: Blackwell Scientific Publications; 1992:49–80.
8. Campbell JA. Dietary management of celiac disease: variations in the gluten-free diet. *J Can Diet Assoc* 1992;53:15–8.
9. Kaukinen K, Collin P, Holm K, et al. Wheat starch-containing gluten-free flour products in the treatment of coeliac disease and dermatitis herpetiformis. A long-term follow-up study. *Scand J Gastroenterol* 1999;34:163–9.
10. Faulkner-Hogg KB, Selby WS, Loblay RH. Dietary analysis in symptomatic patients with coeliac disease on a gluten-free diet: the role of trace amounts of gluten and non-gluten food intolerances. *Scand J Gastroenterol* 1999;34:784–9.
11. Auricchio S, Troncone R. Effects of small amounts of gluten in the diet of coeliac patients. *Panminerva Med* 1991;33:83–5.
12. Thompson T. Questionable foods and the gluten-free diet: survey of current recommendations. *J Am Diet Assoc* 2000;100:463–5.
13. Food and Agricultural Organization of the United Nations, World Health Organization. Understanding the Codex Alimentarius. Available at <http://www.fao.org/docrep/W9114E/W9114E00.htm>. Accessed 3 Mar 2003.
14. Janssen FW. Codex standard for gluten-free products. In: Lohiniemi S, Collin P, Mäki M, editors. *Changing features of coeliac disease*. Tampere (Finland): The Finnish Coeliac Society; 1998:31–6.
15. What is the Codex Alimentarius Commission—Is Codex wheat starch safe for the gluten-free diet/coeliac disease? Available at [http://www.celiac.com/cgi-bin/webc.cgi/st\\_prod.html?p\\_prodid=208&p\\_catid=&sid=91hH9HOIM7Xx665-25103455561.cd](http://www.celiac.com/cgi-bin/webc.cgi/st_prod.html?p_prodid=208&p_catid=&sid=91hH9HOIM7Xx665-25103455561.cd). Accessed 3 Mar 2003.
16. Joint FAO/WHO Food Standards Program. Codex Committee on Nutrition and Foods for Special Dietary Uses. Draft revised standard for gluten-free foods. Pub. No. CX/NFSDU 98/4; July 1998:1–4.
17. Green P, Byfield F. The diagnosis of celiac disease 1998. *Clin Perspec Gastroenterol* 1998;2:133–9.
18. Thompson T. Thiamin, riboflavin, and niacin contents of the gluten-free diet: is there cause for concern? *J Am Diet Assoc* 1999;99:858–62.
19. Logan RF, Rifkind EA, Turner ID, Ferguson A. Mortality in celiac disease. *Gastroenterology* 1989;97:265–71.
20. Nielsen OH, Jacobsen O, Pedersen ER, et al. Non-tropical sprue. Malignant disease and mortality rate. *Scand J Gastroenterol* 1985;20:13–8.
21. Trier JS. Celiac sprue. *N Engl J Med* 1991;325:1709–19.
22. Stokes PL, Prior P, Sorahan TM. Malignancy in relatives of patients with coeliac disease. *Br J Prev Soc Med* 1976;30:17–21.
23. Corrao G, Corazza GR, Bagnardi V, et al. Mortality in patients with coeliac disease and their relatives: a cohort study. *Lancet* 2001;358:356–61.
24. Fasano A. Where have all the American celiacs gone? *Acta Paediatr Suppl* 1996;412:20–4.
25. Not T, Horvath K, Hill ID, et al. Celiac disease risk in the USA: high prevalence of antiendomysium antibodies in healthy blood donors. *Scand J Gastroenterol* 1998;33:494–8.
26. Mylotte M, Egan-Mitchell B, McCarthy CF, McNicholl B. Coeliac disease in the West of Ireland. *Br Med J* 1973;3:498–9.
27. Johnston SD, Watson RG, McMillan SA, et al. Coeliac disease detected by screening is not silent—simply unrecognized. *QJM* 1998;91:853–60.
28. Catassi C, Fabiani E, Ratsch IM, et al. The coeliac iceberg in Italy. A multicentre antigliadin antibodies screening for coeliac disease in school-age subjects. *Acta Paediatr Suppl* 1996;412:29–35.
29. Swinson CM, Slavin G, Coles EC, Booth CC. Celiac disease and malignancy. *Lancet* 1983;1:111–5.
30. Pricolo VE, Mangi AA, Aswad B, Bland KI. Gastrointestinal malignancies in patients with celiac sprue. *Am J Surg* 1998;176:344–7.
31. Holmes GK. Celiac disease and type 1 diabetes mellitus—the case for screening. *Diabet Med* 2001;18:169–77.
32. Talal AH, Murray JA, Goeken JA, Sivitz WI. Celiac disease in an adult population with insulin-dependent diabetes mellitus: use of endomysial antibody testing. *Am J Gastroenterol* 1997;92:1280–4.
33. Hankey GL, Holmes GK. Coeliac disease in the elderly. *Gut* 1994;35:65–7.
34. Catassi C, Fabiani E. The spectrum of coeliac disease in children. *Baillieres Clin Gastroenterol* 1997;11:485–507.
35. Farrell RJ, Kelly CP. Celiac sprue. *N Engl J Med* 2002;346:180–8.
36. Lankisch PG, Martinez Schramm A, Petersen F, et al. Diagnostic intervals for recognizing celiac disease. *Z Gastroenterol* 1996;34:473–7.
37. Dahele A, Ghosh S. Vitamin B<sub>12</sub> deficiency in untreated celiac disease. *Am J Gastroenterol* 2001;96:745–50.
38. Fasano A, Catassi C. Current approaches to diagnosis and treatment of celiac disease: an evolving spectrum. *Gastroenterology* 2001;120:636–51.
39. Volta U, Molinaro N, de Franceschi L, et al. IgA

- anti-endomysial antibodies on human umbilical cord tissue for celiac disease screening. Save both money and monkeys. *Dig Dis Sci* 1995;40:1902–5.
40. Ferreira M, Davies SL, Butler M, et al. Endomysial antibody: is it the best screening test for coeliac disease? *Gut* 1992;33:1633–7.
  41. Grodzinsky E, Hed J, Skogh T. IgA antiendomysium antibodies have a high positive predictive value for celiac disease in asymptomatic patients. *Allergy* 1994;49:593–7.
  42. Dietrich W, Ehnis T, Bauer M, et al. Identification of tissue transglutaminase as the autoantigen of celiac disease. *Nat Med* 1997;3:797–801.
  43. Rostami K, Kaerkaert J, Tiemessen R, et al. Sensitivity of antiendomysium antibodies and antigliadin antibodies in untreated celiac disease: disappointing in clinical practice. *Am J Gastroenterol* 1999;94:888–94.
  44. Uibo O, Uibo R, Kleimola V, et al. Serum IgA anti-gliadin antibodies in an adult population sample. High prevalence without celiac disease. *Dig Dis Sci* 1993;38:2034–7.
  45. Pink IJ, Creamer B. Response to a gluten-free diet of patients with coeliac syndrome. *Lancet* 1967;1:300–4.
  46. Abdulkarim AS, Burgart LJ, See J, Murray JA. Etiology of non-responsive celiac disease: results of a systematic approach. *Am J Gastroenterol* 2002;97:2016–21.
  47. Sategna-Guidetti C, Pulitano R, Grosso S, Ferfaglia G. Serum IgA antiendomysium antibody titres as a marker of intestinal involvement and diet compliance in adult celiac sprue. *J Clin Gastroenterol* 1993;17:123–7.
  48. Sjoberg K, Ericksson KF, Bredberg A, et al. Screening for coeliac disease in adult insulin-dependent diabetes mellitus. *J Intern Med* 1998;243:133–40.
  49. Counsell CE, Taha A, Ruddell WS. Coeliac disease and autoimmune thyroid disease. *Gut* 1994;35:844–6.
  50. Ventura A, Magazzu G, Greco L. Duration of exposure to gluten and risk for autoimmune disorders in patients with celiac disease. SIGEP Study Group for Autoimmune Disorders in Celiac Disease. *Gastroenterology* 1999;117:297–303.
  51. Egan IJ, Walsh SV, Stevens FM, et al. Celiac-associated lymphoma. A single institution experience of 30 cases in the combination chemotherapy era. *J Clin Gastroenterol* 1995;21:123–9.
  52. Rubesin SE, Herlinger H, Saul SH, et al. Adult celiac disease and its complications. *Radiographics* 1989;9:1045–66.
  53. Cellier C, Delabesse E, Helmer C, et al. Refractory sprue, coeliac disease and enteropathy-associated T-cell lymphoma. French Coeliac Disease Study Group. *Lancet* 2000;356:203–8.
  54. Rolny P, Sigurjonsdottir HA, Remotti H, et al. Role of immunosuppressive therapy in refractory sprue-like disease. *Am J Gastroenterol* 1999;94:219–25.
  55. Wahab PJ, Crusius JB, Meijer JW, et al. Cyclosporin in the treatment of adults with refractory coeliac disease—an open pilot study. *Aliment Pharmacol Ther* 2000;14:767–74.

---

*Adapted from Loftus CG, Murray JA. Celiac disease: diagnosis and management. JCOM J Clin Outcomes Manage 2002;9:341–9.*