

Common Musculoskeletal Problems of the Upper Extremity

Bernard Karnath, MD

Musculoskeletal problems are a common reason for outpatient visits, with joint pain being a particularly common complaint. The major focus of the musculoskeletal examination is on the joints of the limbs and on the spine. This article, the first of a 3-part series on the musculoskeletal examination, discusses the examination of the shoulder, elbow, wrist, and hand, and the common musculoskeletal conditions that can occur in each of these regions (Table 1). Subsequent articles will focus on the examination of the lower extremities and the lower back.

GENERAL APPROACH FOR MUSCULOSKELETAL PROBLEMS

Taking a careful history is essential in the diagnosis of musculoskeletal problems. Time of onset and a history of trauma should be investigated. Fractures should always be considered in the differential diagnosis of a patient with a history of trauma or fall.

The examination of each joint should proceed with the following steps: inspection, palpation, range of motion, and special maneuvers.¹ Most examiners follow a routine in which anatomic regions are examined in a sequence (eg, starting with the hand and working upward to the shoulder).² Inspection of the joint may reveal deformities, swelling, erythema, bruising, and muscle atrophy. Palpation of the joint should be performed to detect warmth, tenderness, and crepitus. (*Crepitus* is defined as the grating sensation caused by the rubbing together of dry synovial surfaces of the joints.) Tests for range of motion—both active and passive—are essential components of the musculoskeletal examination. Restrictions in range of motion are usually due to mechanical causes. Special tests for a specific joint may also help in eliciting a diagnosis.³

OSTEOARTHRITIS

Osteoarthritis, also known as degenerative joint disease, is the most prevalent joint disease and can affect

STEPS IN EXAMINATION OF A JOINT

- Inspection
- Palpation
- Range of motion assessment
- Special maneuvers

any joint. Symptomatic disease increases with age. The disease process occurs as articular cartilage is worn away and bone spur formation occurs as a result of joint overuse. Physical trauma and repetitive injury contribute to the development of osteoarthritis of a specific joint. Initially, patients complain of joint stiffness and pain that are made worse by activity and relieved by rest. Stiffness follows inactivity and is usually worse in the morning. The morning stiffness, also known as the *gel phenomenon*, rarely exceeds 30 minutes. Pain is often elicited during range-of-motion maneuvers, and crepitus is often felt during the examination of the joint.

PAINFUL SHOULDER

Shoulder pain is the second most common orthopaedic complaint in primary care and is second only to low back pain.⁴ A painful shoulder can be caused by local conditions such as rotator cuff tendinitis, rotator cuff tear, subacromial bursitis, adhesive capsulitis, osteoarthritis, and bicipital tendinitis.

Rotator Cuff Problems

The rotator cuff comprises 4 muscles: the supraspinatus, infraspinatus, teres minor, and subscapularis muscles. Rotator cuff tears may occur as injuries resulting

Dr. Karnath is an Assistant Professor of Internal Medicine, University of Texas Medical Branch, Galveston, TX.

from a fall. They also may occur as a result of impingement syndrome. Causes of impingement include arthritis and calcified ligaments. Tears usually occur in the supraspinatus tendon and infraspinatus tendon.

Range of motion in a patient with a rotator cuff tear is significantly impaired, resulting in limited abduction. Patients may be unable to raise their arm above their head. The patient may instead shrug the shoulder.

In evaluating for the presence of a tear, each muscle of the rotator cuff can be tested against resistance (Figure 1).⁵ Positive tests are indicated by either pain or weakness against resistance. Comparison to the opposite shoulder can be used to determine what is normal strength for that particular patient. The supraspinatus muscle can be tested with abduction against resistance (Figure 1, part A). The infraspinatus and teres minor muscles can be tested with lateral rotation against resistance (Figure 1, part B). The subscapularis muscle can be tested with medial rotation against resistance (Figure 1, part C).

The drop-arm test is another useful test for detecting supraspinatus tears. This is performed by passively abducting the patient's arm, with the elbow straight, and then observing as the patient slowly lowers the arm. If a supraspinatus tear is present, the arm will drop to the side when it reaches a 90-degree angle from the vertical torso.

Rotator cuff tendinitis is caused by inflammation of the supraspinatus tendon, most commonly resulting from repetitive motion. Tenderness is maximal just below the tip of the acromion process. Calcific tendinitis is a specific form of tendinitis that is associated with calcium salt deposition in the periarticular soft tissues and tendons. Although other joints can develop calcium deposits, the shoulder is the most commonly involved joint. Radiography is essential for diagnosis of calcific tendinitis.

Subacromial Bursitis

The subacromial bursa is the primary bursa of the shoulder and is positioned between the acromion and the head of the humerus. Subacromial bursitis can cause shoulder pain. Repetitive throwing and other repetitive activities performed with the arm elevated cause excessive friction of the bursa sac and are common causes of subacromial bursitis. Palpable tenderness of the bursa is a common physical finding. The subacromial bursa can be moved into a palpable position with passive extension of the shoulder (Figure 2).

Bicipital Tendinitis

Bicipital tendinitis results from inflammation of the

Table 1. Differential Diagnosis of Commonly Encountered Upper Limb Conditions

Condition	Major Differentiating Physical Examination Finding
Shoulder	
Rotator cuff tendinitis	Palpable tenderness below acromion process
Rotator cuff tear	Weakness
Subacromial bursitis	Palpable tenderness of bursa
Bicipital tendinitis	Palpable tenderness along bicipital groove
Adhesive capsulitis	Decreased range of motion
Osteoarthritis	Crepitus
Elbow	
Olecranon bursitis	Swelling over the olecranon process
Lateral epicondylitis	Pain with wrist dorsiflexion (Cozen's test)
Medial epicondylitis	Pain with wrist flexion
Ulnar neuropathy	Paresthesias along the lateral aspect of the hand
Osteoarthritis	Crepitus
Hand and wrist	
Osteoarthritis	Heberden's and Bouchard's nodes
Rheumatoid arthritis	Symmetrical joint swelling and tenderness
Carpal tunnel syndrome	Provocative paresthesias (Tinel's sign, Phalen's test)
Dupuytren's contracture	Flexion deformities of 1 or more fingers

long head of the biceps tendon. Shoulder pain and tenderness are common complaints. Tenderness in the bicipital groove can be elicited (Figure 3). The diagnosis of bicipital tendinitis is further confirmed if shoulder pain is exacerbated when the forearm is flexed and supinated against resistance.

Adhesive Capsulitis

Adhesive capsulitis, or *frozen shoulder*, results from fibrosis of the glenohumeral joint capsule. Adhesive capsulitis is defined as a worsening painful shoulder with restricted active and passive range of motion secondary to pain of at least 1 month's duration.⁶ Patients typically present with shoulder pain and progressive decrease in

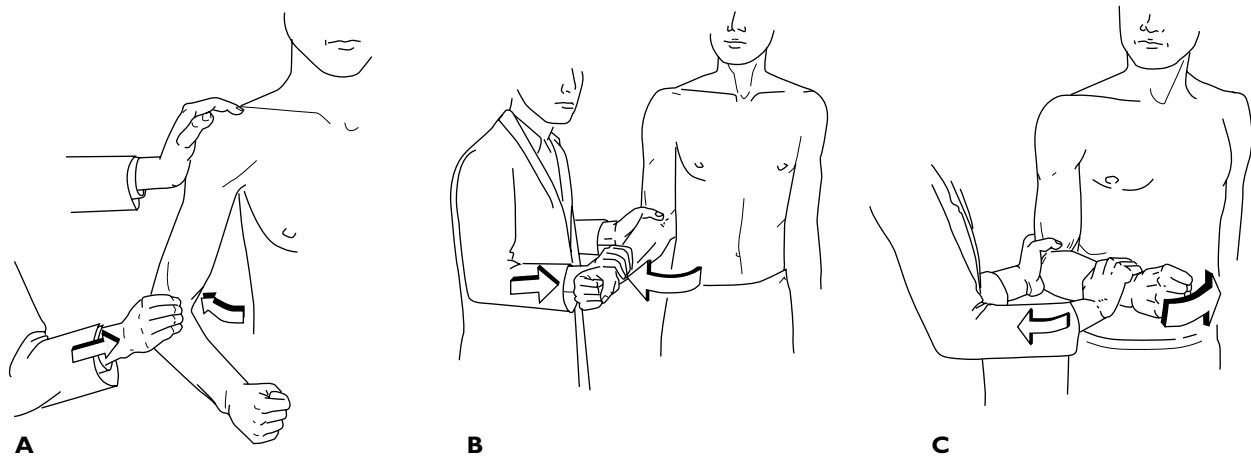


Figure 1. Tests for the rotator cuff. (A) Test for shoulder abduction (supraspinatus muscle). (B) Test for external rotation (infraspinatus and teres minor muscles). (C) Test for internal rotation (subscapularis muscle). (Redrawn with permission from Hoppenfeld S, Hutton R. *Physical examination of the spine and extremities*. New York: Appleton-Century-Crofts; 1976:27–28.)

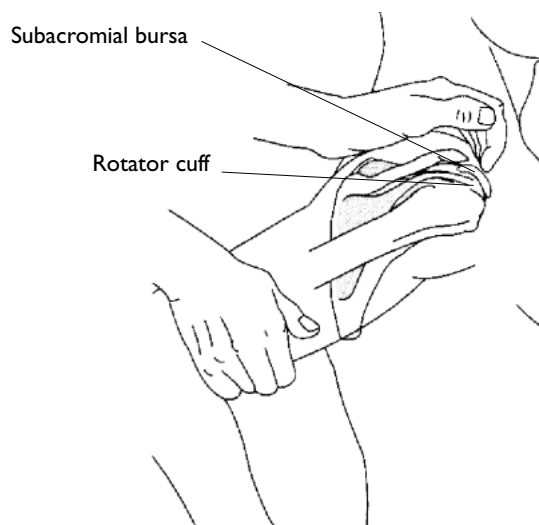


Figure 2. Palpation of the subacromial bursa. (Reprinted with permission from Bickley LS, Hoekelman RA, Bates B. *Bates' guide to physical examination and history taking*. 7th ed. Philadelphia: Lippincott-Raven; 1999:512.)

range of motion without localized tenderness. Adhesive capsulitis includes both a primary and secondary types.⁶ Patients with primary adhesive capsulitis have no significant finding in their history. Patients with secondary adhesive capsulitis most often report that their pain and immobility was preceded by a shoulder injury. The clinical course of adhesive capsulitis is divided into 3 phases: a painful phase, a stiffening phase (which may last up to 1 year), and a phase of resolution. Although adhesive capsulitis generally resolves spontaneously, resolution of

symptoms can take as long as 2 years,⁷ and symptomatic treatment with a nonsteroidal anti-inflammatory drug should be provided.

PAINFUL ELBOW

The elbow joint is normally extended by gravity. In order to examine the elbow, the patient's forearm should be supported so that the elbow is slightly flexed. The elbow should be inspected and any swelling or nodules noted. The epicondyles and olecranon should be palpated for tenderness. Range of motion maneuvers should be performed, including flexion and extension of the elbow and pronation and supination of the forearm. Crepitus and pain during range of motion maneuvers should be noted.

Olecranon Bursitis

The olecranon bursa is a synovium-lined sac that overlies the olecranon process and facilitates gliding of superficial tissues during elbow motion. Inflammation of this bursa can result from constant elbow pressure or repeated use. Olecranon bursitis typically results in painful swelling of the olecranon bursa, although sometimes the swelling is painless. Persons who develop olecranon bursitis are typically involved in manual labor, such as carpentry or construction work, that leads to repetitive trauma of the elbow.^{8,9}

Epicondylitis

Lateral epicondylitis, also known as *tennis elbow*, results from repetitive extension of the wrist or repetitive pronation and supination of the forearm. The site of inflammation is at the attachment of the wrist extensors

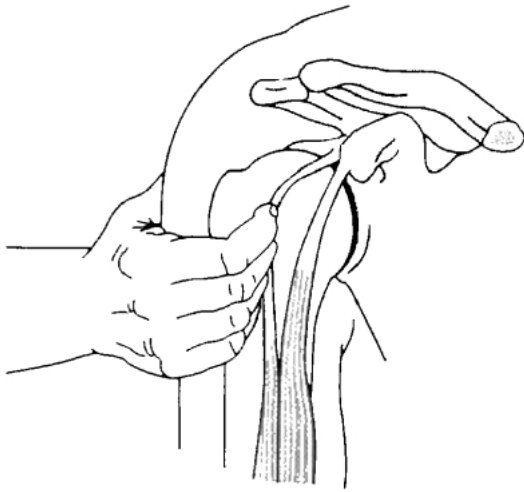


Figure 3. Palpation of the bicipital tendon. (Reprinted with permission from Bickley LS, Hoekelman RA, Bates B. Bates' guide to physical examination and history taking. 7th ed. Philadelphia: Lippincott-Raven; 1999:512.)

at the lateral epicondyle. Cozen's test is used to test for lateral epicondylitis.⁹ It is performed by dorsiflexing the wrist against resistance. Epicondylitis is signified by pain in the area of the lateral epicondyle (**Figure 4**).

Medial epicondylitis—*pitcher's* or *golfer's elbow*—results from activities that require rapid wrist flexion.^{10,11} Pain is increased when wrist flexion is performed under resistance. The site of inflammation is at the origin of the flexor-pronator muscles of the wrist.

Ulnar Neuropathy

Ulnar neuropathy at the elbow (ie, *cubital tunnel syndrome*) is second only to carpal tunnel syndrome in frequency among the entrapment neuropathies.¹² Repetitive mechanical trauma or friction at the medial epicondyle can cause ulnar neuritis, thereby causing compression of the nerve at the epicondylar groove. Patients frequently complain of paresthesias along the distribution of the ulnar nerve, which includes the fifth finger and the lateral aspect of the fourth finger. Examination should focus on palpation of the nerve as it passes through the epicondylar groove, thereby reproducing the paresthesias along the nerve distribution (**Figure 5**).

PAINFUL HANDS AND WRIST

The examination of the hands and wrist begins with inspection for deformities, nodules, and muscle atrophy, followed by palpation of each joint for swelling, boggiess, and tenderness.

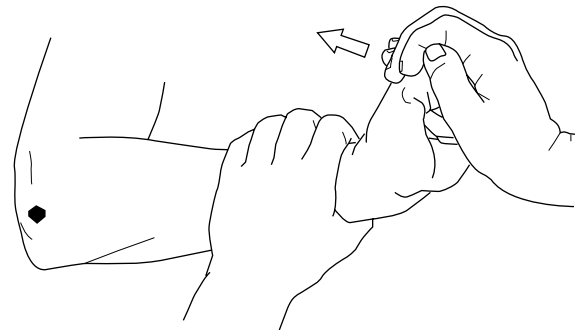

Figure 4. Cozen's test. (Redrawn with permission from McQuillan MA. Musculoskeletal system. In: Judge RD, Wolliscroft JO, Zelenock GB, Zuidema GD, editors. The Michigan manual of clinical diagnosis: the basis of cost-effective medical practice. Philadelphia: Lippincott-Raven; 1998:295.)

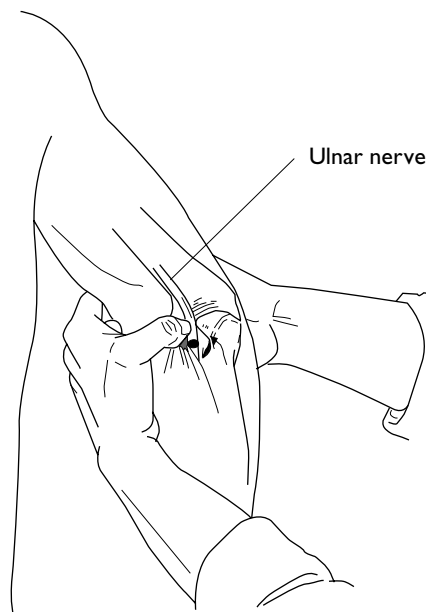


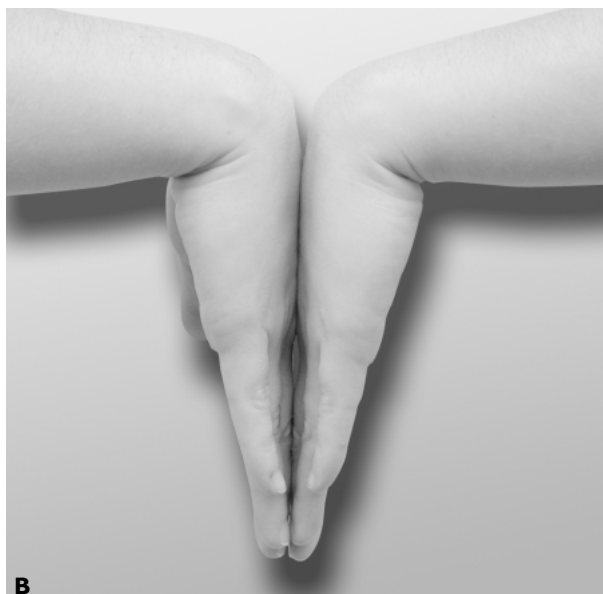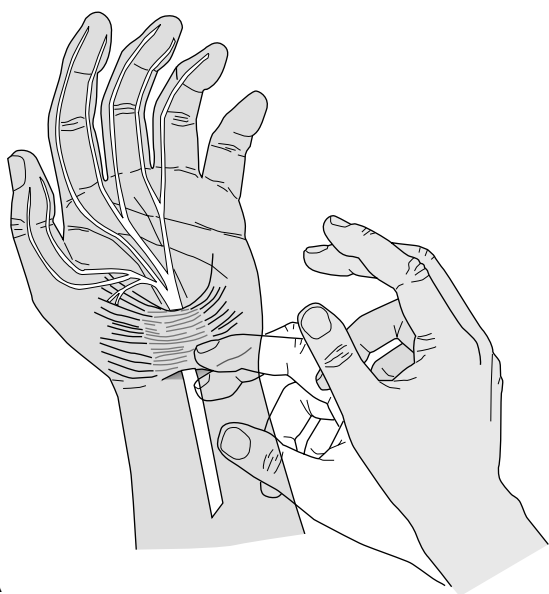
Figure 5. Palpation of the ulnar nerve. (Redrawn with permission from Hoppenfeld S, Hutton R. Physical examination of the spine and extremities. New York: Appleton-Century-Crofts; 1976:43.)

Osteoarthritis

Heberden's and Bouchard's nodes are considered markers for osteoarthritis and are believed to be caused by osteophytes.¹³ Heberden's nodes occur at the distal interphalangeal joints, whereas Bouchard's nodes occur at the proximal interphalangeal joints.

Rheumatoid Arthritis

Rheumatoid arthritis is an inflammatory disease



A
Figure 6. (A) Tinel's sign. (Redrawn from Seidel HM, Ball JW, Dains JE, Benedict GW, editors. *Mosby's guide to physical examination*. 4th ed. St. Louis [MO]: Mosby; 1999:719, with permission from Elsevier Science.) (B) Phalen's test.

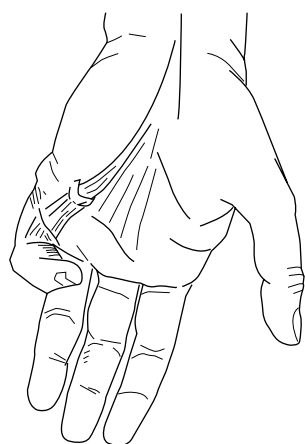

Figure 7. Dupuytren's contracture. Flexion deformity of the fifth metacarpal is shown. (Redrawn with permission from Hoppenfeld S, Hutton R. *Physical examination of the spine and extremities*. New York: Appleton-Century-Crofts; 1976:85.)

affecting mainly synovial membranes of multiple joints. Patients complain of periarticular pain and stiffness that is prominent in the morning but subsides during the day. After months or years, deformities may occur. Symmetrical deformities occur in the proximal interphalangeal joint, metacarpophalangeal joint, and wrist joints, with ulnar deviation of the metacarpophalangeal joints. The joints are symmetrically swollen, boggy, and tender. The most common deformities are ulnar deviation of the fingers, "swan-neck" deformity

(flexion of the distal interphalangeal with extension of the proximal interphalangeal joint), and boutonniere deformity (hyperextension of the distal interphalangeal joint with flexion of the proximal interphalangeal joint).

Carpal Tunnel Syndrome

Pain and numbness in the hand suggests compression of the median nerve in the carpal tunnel. The numbness and tingling develop over the distribution of the median nerve, which includes the palmar surface of the thumb, index finger, middle finger, and the medial aspect of the fourth finger. Carpal tunnel syndrome occurs most often in persons with a history of repetitive use of the hands, but it also can be seen in pregnancy and in systemic diseases such as rheumatoid arthritis, diabetes, amyloidosis, and hypothyroidism.

Tinel's sign and Phalen's test are provocative tests used in the diagnosis of carpal tunnel syndrome (Figure 6). Tinel's sign is elicited by percussing lightly over the median nerve in the carpal tunnel. Phalen's test is conducted by having the patient hold the wrist in acute flexion for 60 seconds. Either test is considered positive if a tingling sensation in the distribution of the median nerve occurs. Phalen's test has a greater sensitivity and specificity than Tinel's sign.¹⁴

Dupuytren's Contracture

Dupuytren's contracture is caused by a thickening and contraction of the fascia of the hand (Figure 7).¹⁵

(continued on page 71)

(from page 52)

It most often occurs in Caucasian men over the age of 50 years, and a family history of the condition is often present. A key early physical finding is a palmar nodule. Digital nodules may also be found near the proximal interphalangeal joint. The nodular development is eventually followed by the formation of a cord, which gradually contracts. Without treatment, flexion deformities of 1 or several digits may occur. **HP**

REFERENCES

1. McRae R. Clinical orthopaedic examination. 4th ed. New York: Churchill Livingstone; 1997.
2. Hoppenfeld S, Hutton R. Physical examination of the spine and extremities. New York: Appleton-Century-Crofts; 1976.
3. Konin JG, Wiksten DL, Isear JA. Special tests for orthopedic examination. Thorofare (NJ): Slack; 1997.
4. Howard TM, O'Connor FG. The injured shoulder. Primary care assessment. Arch Fam Med 1997;6:376–84.
5. Bickley LS, Hoekelman RA. Bates' guide to physical examination and history taking. 7th ed. Philadelphia: Lippincott-Raven; 1999.
6. Pearsall AW, Speer KP. Frozen shoulder syndrome: diagnostic and treatment strategies in the primary care setting. Med Sci Sports Exerc 1998;30(4 Suppl): S33–9.
7. Bunker TD. Frozen shoulder: unravelling the enigma. Ann R Coll Surg Engl 1997;79:210–3.
8. Watrous BG, Ho G Jr. Elbow pain. Prim Care 1988; 15:725–35.
9. Seidel HM, Ball JW, Dains JE, Benedict GW, editors. Mosby's guide to physical examination 4th ed. St. Louis (MO): Mosby; 1999.
10. Chumbley EM, O'Connor FG, Nirschl RP. Evaluation of overuse elbow injuries. Am Fam Physician 2000;61: 691–700.
11. Colman WW, Strauch RJ. Physical examination of the elbow. Orthop Clin North Am 1999;30:15–20.
12. Bradshaw DY, Shefner JM. Ulnar neuropathy at the elbow. Neurol Clin 1999;17:447–61.
13. Alexander CJ. Heberden's and Bouchard's nodes. Ann Rheum Dis 1999;58:675–8.
14. Kuschner SH, Ebramzadeh E, Johnson D, et al. Tinel's sign and Phalen's test in carpal tunnel syndrome. Orthopedics 1992;15:1297–302.
15. Rayan GM. Clinical presentation and types of Dupuytren's disease. Hand Clin 1999;15:87–96.

Copyright 2003 by Turner White Communications Inc., Wayne, PA. All rights reserved.