

## Eosinophilic Gastroenteritis in a Patient with Bronchial Asthma

*Maria Carmina C. Garcia, MD*

*Ryland P. Byrd, Jr, MD*

*Cheryl L. Fields, MD, FCCP*

*George A. Youngberg, MD*

*Thomas M. Roy, MD*

**E**osinophilic gastroenteritis is a rare condition of unknown etiology characterized by eosinophilic infiltration of the gastrointestinal tract and resultant gastrointestinal dysfunction of mild to disabling severity. Approximately 90% of patients with eosinophilic gastroenteritis also have a peripheral eosinophilia.<sup>1</sup> An atopic predisposition to eosinophilic gastroenteritis is suggested by its association with allergic rhinitis, atopic dermatitis, and elevated serum levels of IgE.

Eosinophils can cause a heterogeneous group of disorders involving other major organ systems as well, including the respiratory system. For example, although many cells are involved in the pathogenesis of asthma, the eosinophil is the most characteristic inflammatory cell of this disease; recent studies have emphasized the critical role played by airway inflammation in the pathogenesis of asthma.<sup>2,3</sup> Asthma has even been described as chronic eosinophilic bronchitis. Disease activity in asthma has been correlated with increased eosinophil counts on bronchoalveolar lavage, as well as increased production of peripheral blood and sputum.

Despite the fact that eosinophils and IgE antibodies play a central role in both eosinophilic gastroenteritis and asthma, the occurrence of the former disorder in patients with asthma is uncommon. In addition, the coexistence of the 2 diseases, both characterized by peripheral eosinophilia and a positive response to glucocorticosteroid therapy, might make the recognition of eosinophilic gastroenteritis in a patient with asthma more difficult.

This report presents the case of a woman with moderately severe, life-long asthma who developed eosinophilic gastroenteritis. The epidemiology, etiology, diagnosis, and treatment of eosinophilic gastroenteritis are discussed, as is the difficulty in recognizing the disorder when bronchial asthma coexists. Moreover, the

need to eliminate Churg-Strauss syndrome (ie, allergic granulomatous angiitis) as a cause of any airway and gastrointestinal dysfunction—especially when significant eosinophilia is present—is emphasized.

### CASE PRESENTATION

A 76-year-old woman with chronic asthma reported a 4-week history of intractable diarrhea, anorexia, and weight loss. She described her bowel movements as watery but said there was no noticeable blood or mucous mixed with the stool. She reported no nausea, vomiting, abdominal pain, or fever and had not recently traveled or consumed any raw or uncooked foods. She was taking no herbal supplements or over-the-counter medications.

### History

Medical history was significant for asthma of 50 years' duration, for which the patient had been treated successfully on many occasions with corticosteroid pulse therapy. Other notable historical findings included allergic rhinitis, nasal polyposis, sinusitis, and hypertension. She had allergies to multiple drugs, including aspirin, nonsteroidal anti-inflammatory drugs, penicillin, ciprofloxacin, cefaclor, cephalixin, nitrofurantoin, and metronidazole. Although a diagnosis of Samter's syn-

---

*Dr. Garcia is a Pulmonary and Critical Care Fellow, Dr. Byrd is an Associate Professor, and Dr. Fields is an Associate Professor of Medicine, James H. Quillen College of Medicine, East Tennessee State University, Johnson City, TN. Dr. Youngberg is the Associate Chief of Staff for Research, James H. Quillen Veterans Affairs Medical Center, Mountain Home, TN. Dr. Roy is a Professor of Medicine, James H. Quillen Veterans Affairs Medical Center, Mountain Home, TN, and Chief of Pulmonary/Critical Care Medicine, James H. Quillen College of Medicine, East Tennessee State University, Johnson City, TN.*

drome<sup>4</sup> had been considered several years earlier, given her asthma, nasal polyposis, and aspirin sensitivity, it had since been excluded as a possibility. On previous skin testing, she had a positive response to multiple antigens. However, she had no known food allergy. Her usual medications included triamcinolone, administered through a metered-dose inhaler, 2 puffs 4 times daily; theophylline 100 mg twice daily; flunisolide 2 puffs to each nostril twice daily, fosinopril 10 mg once daily; and albuterol as needed, administered through a metered-dose inhaler, 2 puffs 4 times daily. There was no family history of asthma or allergies.

### Physical Examination

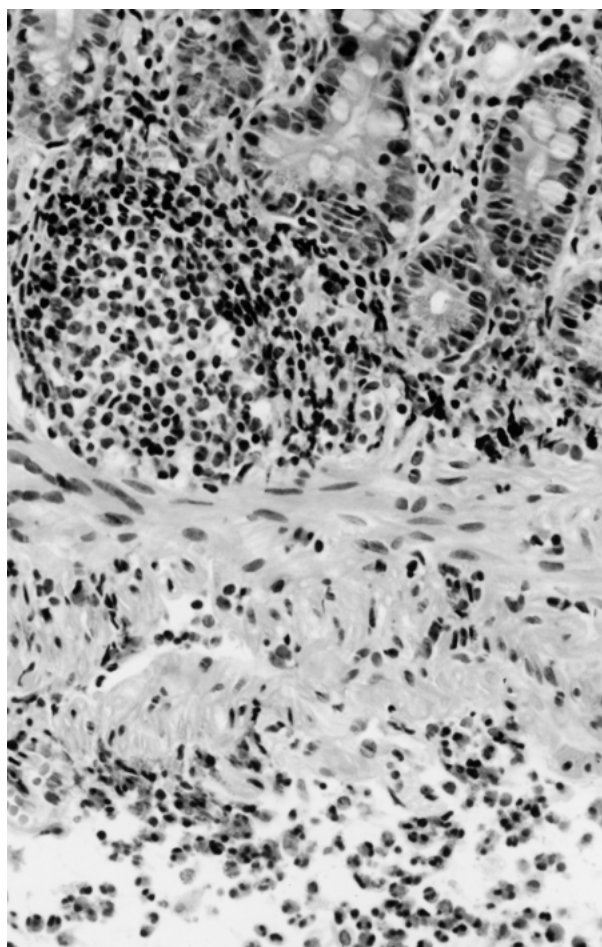
The patient appeared thin, frail, and chronically ill. She was afebrile. Blood pressure was 154/100 mm Hg, pulse was 97 bpm, and respiratory rate was 18 breaths/min. Breath sounds were distant but clear on auscultation, and cardiovascular examination revealed no abnormalities. Bowel sounds were normal. Her abdomen was soft and nontender; she had a ventral hernia, but no hepatosplenomegaly or masses were detected on palpation. Her stool was negative for occult blood.

### Laboratory Examination

Leukocyte count was  $14.5 \times 10^3/\text{mm}^3$ , with 30% eosinophils. Hemoglobin, hematocrit, and serum electrolyte levels were within normal range. Total serum protein and serum albumin levels were low, at 5.0 g/dL and 2.9 g/dL, respectively. Erythrocyte sedimentation rate was 1 mm/h. Results of urinalysis showed no abnormalities, and examination of the stool revealed no ova or parasites. A stool culture tested negative for both *Clostridium difficile* and *C. difficile* A-B toxins.

### Radiographic and Endoscopic Studies

Computed tomography of the abdomen suggested that the walls of the small intestine were thickened. However, no abnormalities were seen on an upper gastrointestinal barium study. Ultrasound examination of the right upper abdominal quadrant showed no abnormalities. Endoscopic examination of the colon failed to reveal a cause of the patient's diarrhea; no lesions were seen during esophagogastroduodenoscopy. However, histologic analysis of random endoscopic biopsy specimens of the mucosa of the stomach and small intestine showed a chronic inflammatory cell infiltrate, with aggregates of eosinophils within the lamina propria and an edematous submucosa with numerous eosinophils. A photomicrograph of a biopsy specimen is shown in **Figure 1**. Based on this histo-



**Figure 1.** Hematoxylin and eosin stain of an endoscopic biopsy specimen from the case patient documenting marked eosinophilic infiltration and edema of the submucosa, with an occasional eosinophil seen in the muscularis mucosa and mucosal layers (original magnification  $\times 400$ ).

logic picture, a diagnosis of eosinophilic gastroenteritis was made.

### Treatment and Outcome

The patient was treated with a pulse of prednisone, administered orally. Her diarrhea subsided soon after she started taking the corticosteroid. Two years later, the patient continues to have periodic asthmatic exacerbations but has not had symptomatic recurrence of eosinophilic gastroenteritis.

## DISCUSSION

### Epidemiology

Eosinophils have been implicated in a broad range of disorders, including allergic conditions such as asthma

and inflammatory diseases such as eosinophilic gastroenteritis. These disease processes are characterized by an accumulation of eosinophils in tissues. Eosinophilic gastroenteritis was first described in 1937,<sup>5</sup> but since that time, there have been fewer than 300 cases described.<sup>6</sup> A rare inflammatory disorder that can affect both adults and children, eosinophilic gastroenteritis is diagnosed most frequently in patients age 20 to 50 years. Both sexes are equally affected.<sup>7,8</sup>

Eosinophilic gastroenteritis occasionally has been observed in patients with asthma.<sup>6,9,10</sup> There have been only 2 patients with analgesic-induced asthma and concomitant eosinophilic gastroenteritis described in the medical literature.<sup>11</sup> Consequently, further observations are necessary before a firm correlation between eosinophilic gastroenteritis and aspirin-sensitive asthma can be established.

### **Etiology**

Eosinophilic gastroenteritis is characterized by peripheral eosinophilia and a patchy and variable eosinophilic infiltration of the gastrointestinal mucosa.<sup>12</sup> Eosinophils from tissues and blood preferentially distribute themselves in the stomach and small intestine. However, any site in the gastrointestinal tract, from the esophagus to the colon, can be involved.<sup>13</sup> Some authors have postulated that the accumulation of eosinophils at the tissue surface in the gastrointestinal tract allows release of toxic eosinophilic cationic proteins, which cause destruction of the intestinal epithelium.<sup>14</sup> Cationic proteins also act as chemotactic factors, recruiting and activating mast cells; this process results in further eosinophilic activation.

A possible mechanism of eosinophilic gastroenteritis involves IgE-mediated activation of mast cells in the gastrointestinal tract.<sup>15</sup> Mast cells are normal components of the gastrointestinal tract, with a defined influence on gastrointestinal motility, angiogenesis, hematopoiesis, fibrosis, and inflammation. Histamine released by mast cell degranulation is a mediator of cellular pathologic eosinophilic infiltrates. In fact, the mast cell is essential to eosinophilic chemotaxis and activation. Patients with eosinophilic gastroenteritis were shown by histochemical and immunohistochemical methods to have a large mast cell population, suggesting a definite role for mast cells in the pathogenesis of the disease.<sup>16</sup>

IgE mediation also might account for the presence of eosinophilic gastroenteritis when an allergic response to food, drugs, or toxins is implicated. Approximately 50% of patients with eosinophilic gastroenteritis have an associated atopic disorder, such as allergic rhinitis, atopic dermatitis, eczema, or urticaria; a history

of allergy was present in 52% of these patients. Thus, in some patients, eosinophilic gastroenteritis most likely represents an allergic phenomenon.<sup>7,8,12</sup> According to some studies, food antigens can cause eosinophilic infiltration<sup>9</sup> and hypersensitivity to agents such as gold salts, azathioprine, and gemfibrozil.<sup>6,17,18</sup> Support for the allergic phenomenon theory includes relief of symptoms and even resolution of eosinophilic gastroenteritis once the suspected allergen is eliminated.

However, IgE mediation might not be the only mechanism of eosinophilic gastroenteritis, because eosinophils independent of IgE can directly release various mediators known to be tissue toxins, such as eosinophilic cationic protein, eosinophilic peroxidase, and major basic protein. In addition, eosinophils synthesize an array of cytokines (eg, interleukin 1, transforming growth factors) with homeostatic and pathobiologic roles in the gastrointestinal tract.<sup>19</sup> Large numbers of patients with eosinophilic gastroenteritis do not show an atopic predisposition, and removal of suspected antigens does not always result in clinical improvement. Consequently, despite the fact that 50% of patients with eosinophilic gastroenteritis have an atopic predisposition, the precise etiology of the disorder is elusive in many cases.<sup>20</sup>

### **Clinical Presentation**

The majority of patients with eosinophilic gastroenteritis are adults age 20 to 50 years who have nonspecific gastrointestinal symptoms correlating with a classification scheme based on (1) the depth of mucosal infiltration by the eosinophils, (2) the pattern of involvement (diffuse, localized), and (3) the location of the disease.<sup>21</sup> The stomach is the most frequent site of involvement, followed by the small intestine, the duodenum, and (rarely) the colon. Diffuse mucosal infiltration by eosinophils is the most common pattern, resulting in symptoms of abdominal pain (77%), nausea and vomiting (48%), and diarrhea (42%).<sup>22</sup> Other symptoms include dyspepsia, weight loss, malabsorption syndrome, anemia, bleeding, protein-losing enteropathy, esophagitis, and intestinal perforation.<sup>22</sup>

Eosinophilic infiltration of the muscularis propria and serosa of the intestinal wall occurs less frequently than does infiltration of the mucosa; eosinophilic gastroenteritis involving the muscle layer often involves the gastric antrum, and affected patients can present with pyloric or small-bowel obstruction.<sup>23</sup> Involvement of the subserosal layer is the rarest form of eosinophilic gastroenteritis and is associated with development of eosinophilic ascites.<sup>10</sup>

### **Diagnostic Methods**

The diagnosis of eosinophilic gastroenteritis is suggested by a peripheral eosinophilia that is present in 90% of cases. The erythrocyte sedimentation rate is usually within normal limits. Immunoglobulin analysis has shown IgE levels to be variably elevated, depending on the presence or absence of atopy.

Suggestive radiographic findings also depend on the depth of intestinal wall involvement and the site affected. The most common radiographic findings in cases of eosinophilic gastroenteritis predominantly involve mucosal and submucosal disease, with changes seen in the folds of the antrum and small intestine. On contrast studies, the mucosal folds of the gastric antrum and small intestine are edematous, with thickening, widening, or (sometimes) complete effacement. When involvement of the muscularis propria predominates, typical radiographic findings are rigidity, stenosis, and dysmotility of the antrum or small intestine. Unfortunately, the various radiographic findings are not pathognomonic of eosinophilic gastroenteritis. For example, features commonly identified in the small intestine (eg, thickening and flattening of the valvulae conniventes, filling defects, strictures, ulceration, polypoid lesions, rigidity of the ileocecal valve) are similar to findings typical of Crohn's disease.<sup>16</sup>

Although the diagnosis of eosinophilic gastroenteritis can be suggested by the presence of gastrointestinal symptoms with peripheral eosinophilia in the absence of parasitism and by radiographic findings, it is established only by histopathologic evidence of eosinophilic infiltration of the intestinal wall. Because of the patchy distribution of this disorder and the frequently normal-appearing mucosa on esophagogastroduodenoscopy, obtaining random multiple biopsy specimens from the gastrointestinal tract is recommended. Although eosinophils are a normal constituent of the gastrointestinal tract, aggregation with infiltration of the mucosal layers, the serosa, or the muscle layers is not normal. There is no agreement regarding how many eosinophils per high power field are required to make the diagnosis (suggestions range from 10 to 50), but clusters of eosinophils are unusual in the submucosa, muscle coat, and serosa. Such an aggregation of eosinophils, in the absence of vasculitis and parasitism, establishes the diagnosis of eosinophilic gastroenteritis.<sup>12</sup>

### **Diagnostic Challenges**

Eosinophilic gastroenteritis should be strongly considered when an infiltrative process involving the antrum of the stomach, the small intestine, or both is seen in a young person with peripheral eosinophilia and a

history of allergy. The disease often is difficult to diagnose because of its nonspecific symptoms, but this diagnostic challenge can be met with an orderly approach that first eliminates other systemic disorders that might cause peripheral eosinophilia. In this regard, some investigators have suggested that eosinophilic gastroenteritis might be a form of a collagen vascular disorder that is similar to Churg-Strauss syndrome (ie, allergic granulomatous angiitis).<sup>24</sup> Churg-Strauss syndrome is characterized by multiorgan disease, hypereosinophilia, and systemic vasculitis in patients with asthma-like symptoms and allergic rhinitis. Because having Churg-Strauss disease or asthma does not preclude the possibility of having eosinophilic gastroenteritis, multiple biopsies of the mucosa of the stomach and small intestine are imperative for establishing a diagnosis of eosinophilic gastroenteritis.<sup>24</sup> There have been several cases in the literature of patients with preexisting asthma and peripheral eosinophilia in whom eosinophilic gastroenteritis was diagnosed by fiberoptic endoscopic biopsies.<sup>25</sup>

### **Treatment**

Patients with eosinophilic gastroenteritis should be instructed to avoid any suspected food allergen. Elimination or elemental diets are effective in patients in whom symptoms are aggravated by specific dietary intake. When an allergen cannot be identified, corticosteroid therapy is the mainstay of treatment for the disease.<sup>26</sup> There is no established duration of treatment, but a short course of high-dose corticosteroid therapy results in a 90% clinical remission rate.

The overall prognosis for patients with eosinophilic gastroenteritis is favorable, and even patients with ascites respond dramatically to corticosteroid therapy.<sup>27</sup> The case patient responded well to corticosteroid therapy and has had no known relapse following her initial treatment. Unfortunately, relapse does occur in up to 50% of patients. Often, these cases can be managed by resumption of corticosteroid treatment at lower doses. The exclusion of parasitism as a cause of the eosinophilic gastroenteritis is, of course, necessary prior to the institution of corticosteroid therapy to avoid the dissemination of parasites.

Sodium cromoglycate and ketotifen also have been used to treat eosinophilic gastroenteritis, but the effectiveness of these drugs has yet to be confirmed. Sodium cromoglycate, taken orally, is absorbed only slightly and, thus, its fundamental action must be exerted locally. However, the limited adverse effects of these agents make them an attractive alternative to corticosteroids in the treatment of patients with mild eosinophilic gastroenteritis.<sup>28</sup>

Leukotrienes have been implicated in the etiology of eosinophilic gastroenteritis. Thus, it seems reasonable to assume that leukotriene inhibitors might be an additional therapeutic option. However, thus far there has been only 1 case report documenting the successful treatment of eosinophilic gastroenteritis with a leukotriene inhibitor.<sup>29</sup> Although this patient responded remarkably well, further research is needed to clarify the role of leukotriene modifiers in the treatment of eosinophilic gastroenteritis.

Finally, surgical resection of the involved gastrointestinal segment may be necessary when obstruction or perforation of the small intestine is involved.<sup>23</sup> Most cases of obstruction occur in the stomach and small intestine. In a review of 220 cases of eosinophilic gastroenteritis, the overall surgical intervention rate was 44%<sup>29</sup>; however, 43% of the patients who underwent surgery had continued symptoms during later follow-up. Because of this fact and because life-threatening complications are very rare, resection of the diseased intestinal segment is reserved for medically refractory cases complicated by obstruction or perforation.<sup>29</sup>

## CONCLUSION

Eosinophilic gastroenteritis is a rare condition of unknown etiology characterized by peripheral eosinophilia, eosinophilic infiltration of the gastrointestinal tract, and abnormalities of gastrointestinal function. When peripheral eosinophilia is present because of preexisting asthma, physicians must consider eosinophilic gastroenteritis as a possible cause of gastrointestinal signs and symptoms, including obstruction. Histopathologic documentation of eosinophilic infiltration of the gastrointestinal tract should be obtained. Patients with mild and sporadic symptoms can usually be managed with assurance and observation. Patients with more disabling symptoms usually can be effectively treated with corticosteroid therapy. Surgical intervention might be necessary in patients with obstructive complications or refractory disease. **HP**

## REFERENCES

- Miyamoto T, Shibata T, Matsuura S, et al. Eosinophilic gastroenteritis with ileus and ascites. *Intern Med* 1996;10:779-82.
- Muro S, Minshall EM, Hamid QA. The pathology of chronic asthma. *Clin Chest Med* 2000;21:225-44.
- Wardlaw AJ, Brightling C, Green R, et al. Eosinophils in asthma and other allergic diseases. *Br Med Bull* 2000;56:985-1003.
- Zeitz HJ. Bronchial asthma, nasal polyps, and aspirin sensitivity: Samter's syndrome. *Clin Chest Med* 1988;9:567-76.
- Kajjjer R. Zur kenntnis der allergischen Affectioner des ma Verdauungskanal von Standpunkt desima Chirurgen aus. *Arch Klin Chir* 1937;188:36-64.
- Lee JY, Medellin MV, Tumpkin C. Allergic reaction to gemfibrozil manifesting as eosinophilic gastroenteritis. *South Med J* 2000;93:807-8.
- Lee M, Hodges WG, Huggins TL, Lee EL. Eosinophilic gastroenteritis. *South Med J* 1996;89:189-94.
- Gay SP, Shaffer HA Jr, Futterer SF, et al. Gastrointestinal case of the day. Eosinophilic gastroenteritis. *Am J Roentgenol* 1996;167:241, 244.
- Park HS, Kim HS, Jang HJ. Eosinophilic gastroenteritis associated with food allergy and bronchial asthma. *J Korean Med Sci* 1995;10:216-9.
- Tai YG, Lui JD, Lin KY, et al. Eosinophilic gastroenteritis with eosinophilic ascites: report of a case. *J Formos Med Assoc* 1990;89:901-4.
- Nakahama H, Nakamura H, Kuribayashi K, et al. Two cases of eosinophilic gastroenteritis associated with analgesic-induced bronchial asthma. *Respirology* 1998;3:95-7.
- Blackshaw AJ, Levison DA. Eosinophilic infiltrates of the gastrointestinal tract. *J Clin Pathol* 1986;39:1-7.
- Matsushita M, Hajiro K, Morita Y, et al. Eosinophilic gastroenteritis involving the entire digestive tract. *Am J Gastroenterol* 1995;90:1868-70.
- Bischoff SC, Mayer J, Nguyen QT, et al. Immunohistological assessment of intestinal eosinophil activation in patients with eosinophilic gastroenteritis and inflammatory bowel disease. *Am J Gastroenterol* 1999;94:3521-9.
- Oyaizu N, Uemura Y, Izumi H, et al. Eosinophilic gastroenteritis. Immunohistochemical evidence for IgE mast cell-mediated allergy. *Acta Pathol Jpn* 1985;35:759-66.
- Kristopaitis T, Neghme C, Yong SL, et al. Giant antral ulcer: a rare presentation of eosinophilic gastroenteritis—case report and review of the literature. *Am J Gastroenterol* 1997;92:1205-8.
- Martin DM, Goldman JA, Gilliam J, et al. Gold-induced eosinophilic enterocolitis: response to oral chromolyn sodium. *Gastroenterol* 1981;80:1567-70.
- Riedel RR, Schmitt A, de Jonge JP, Hartmann A. Gastrointestinal type I hypersensitivity to azathioprine. *Klin Wochenschr* 1990;68:50-2.
- Walsh GM. Advances in the immunobiology of eosinophils and their role in disease. *Crit Rev Clin Lab Sci* 1999;36:453-96.
- Cello JP. Eosinophilic gastroenteritis—a complex disease entity. *Am J Med* 1979;67:1097-104.
- Klein NC, Hargrove RL, Sleisenger MH, Jeffries GH. Eosinophilic gastroenteritis. *Medicine (Baltimore)* 1970;49:299-319.
- Case records of the Massachusetts General Hospital. Weekly clinicopathological exercises. Case 20-1992. A 24-year-old man with asthma and bouts of epigastric pain, nausea, and vomiting. *N Engl J Med* 1992;326:1342-9.
- Shweiki E, West JC, Klena JW, et al. Eosinophilic gastroenteritis presenting as an obstructing cecal mass—a case report and review of literature. *Am J Gastroenterol*

(continued on page 54)

(from page 36)

- 1999;94:3644-5.
24. Kurita M, Niwa Y, Hamada E, et al. Churg-Strauss syndrome (allergic granulomatous angiitis) with multiple perforating ulcers of the small intestine, multiple ulcers of the colon, and mononeuritis multiplex. *J Gastroenterol* 1994;29:208-13.
  25. Neustrom MR, Friesen C. Treatment of eosinophilic gastroenteritis with montelukast. *J Allergy Clin Immunol* 1999;104:506.
  26. Fraile G, Rodriguez-Garcia JL, Beni-Perez R, Redondo C. Localized eosinophilic gastroenteritis with necrotizing granulomas presenting as acute abdomen. *Postgrad Med J* 1994;70:510-2.
  27. Kuri K, Lee M. Eosinophilic gastroenteritis manifesting with ascites. *South Med J* 1994;87:956-7.
  28. Perez-Millan A, Martin-Lorente JL, Lopez-Morante A, et al. Subserosal eosinophilic gastroenteritis treated efficaciously with sodium cromoglycate. *Dig Dis Sci* 1997;42:342-4.
  29. Naylor AR. Eosinophilic gastroenteritis. *Scott Med J* 1990;35:163-5.

Copyright 2001 by Turner White Communications Inc., Wayne, PA. All rights reserved.