

Endomyocardial Fibrosis in an HIV-Infected Patient

Mahendra Gupta, MD

Parul Gupta, MD

Raman Kumar, MD

Feridoun Rezai, MD

Endomyocardial fibrosis (EMF) is a restrictive cardiomyopathy characterized by endocardial fibrotic thickening that usually affects the apex of one or both ventricles. EMF has been reported in tropical and subtropical regions of Africa as well as in India, Brazil, Columbia, and Sri Lanka. EMF is uncommon in the United States; however, this cardiomyopathy has been reported in white patients, even in the absence of prior residence in tropical areas.¹ EMF has not been previously reported in HIV-infected patients. HIV commonly involves the heart and may cause dilated, but not restrictive, cardiomyopathy. A characteristic echocardiographic finding of EMF is obliteration of the ventricular apical region. This report presents a case of EMF with diagnostic echocardiographic findings in an HIV-infected patient. The etiology and pathophysiology of EMF, diagnostic considerations, and treatment are reviewed.

CASE PRESENTATION

A 48-year-old man presents with a 1-month history of nonproductive cough and exertional dyspnea. He has serologic evidence of HIV infection, and his CD4 count is 93 cells/mm³.

Physical Examination

Physical examination is unremarkable, except for an enlarged liver and edema of the feet. Cardiac examination reveals normal heart sounds, without an S₃ or S₄ gallop. No audible murmur is noted.

Laboratory and Radiographic Evaluation

Laboratory tests reveal the following: leukocyte count, 2200 cells/mm³ without eosinophilia; blood urea nitrogen, 7 mg/dL; and creatinine, 0.6 mg/dL. Chest radiograph is normal, and electrocardiogram shows poor R-wave progression in precordial leads.

Echocardiography reveals a mildly dilated right atrium and right ventricle and a mass filling the right and left ventricular apex suggestive of EMF (**Figure 1**).

Treatment and Outcome

The patient is treated with diuretics, and his acute symptoms improve.

DISCUSSION

HIV and AIDS are associated with several cardiac complications, including dilated cardiomyopathy and myocarditis. According to a 1991 study, no specific etiologic factor was found for myocarditis in 80% of HIV-infected patients with myocarditis.² Myocardial opportunistic pathogens—viruses, bacteria, protozoa, and fungi—were present in 15% to 20% of patients.² However, none of these pathogens causes EMF.

The most common endocardial lesion reported in AIDS patients is nonbacterial thrombotic endocarditis.³ Restrictive cardiomyopathy with EMF has not been reported in AIDS patients. Thus, ascertaining HIV as an etiologic factor in the development of EMF is difficult; in this case report, EMF in the context of HIV may be only a coincidence. However, because the patient in this case does not have eosinophilia and has no history of residing in a tropical area, it may be possible that HIV contributed to his development of EMF.

Etiology and Pathophysiology

EMF is a progressive, restrictive cardiomyopathy.

Dr. Mahendra Gupta is Chief Resident, Internal Medicine, Dr. Parul Gupta is Resident, Internal Medicine, Dr. Kumar is Cardiology Fellow, and Dr. Rezai is Director, Cardiology, Division of Cardiology, Department of Medicine, Jersey City Medical Center, Mount Sinai School of Medicine Jersey City, NJ.

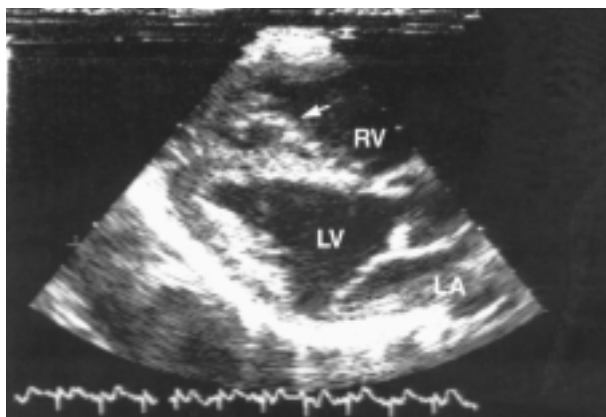


Figure 1. Echocardiography (parasternal long axis view) demonstrates a mass filling the right ventricular apex extending to the tricuspid valve apparatus (arrow). LA = left atrium; LV = left ventricle; RV = right ventricle.

EMF is characterized by a fibrous endocardial lesion of the right, left, or both ventricles, and EMF often involves atrioventricular valves. Several etiologic hypotheses for EMF exist, including filarial infection, eosinophilia, and high cerium levels with low concentrations of magnesium apparently found in endemic areas.^{4,5} Cerium apparently stimulates collagen synthesis, which could account for the fibrotic response in EMF. Magnesium deficiency promotes the absorption of cerium and enhances its toxicity.⁶

Hypereosinophilia, which is known to cause EMF, is characterized by three stages.⁷⁻⁹ The first phase of hypereosinophilia is a necrotic stage characterized by an intense myocarditis; this stage is followed by a thrombotic stage, during which myocarditis has receded. The third and final stage is fibrosis, presenting all the features of EMF. The intracytoplasmic granule content (ie, activated eosinophil) is probably responsible for the toxic damage to the heart.^{10,11}

HIV may cause a similar inflammatory myocarditis in the absence of eosinophilia, which may subsequently lead to EMF and restrictive cardiomyopathy. Several studies have shown that HIV may infect heart muscle and cause myocarditis. Herskowitz et al¹² obtained endomyocardial biopsy from patients infected with HIV-1 and with unexplained left ventricular dysfunction and congestive heart failure. Of the 33 biopsy samples, 17 (51%) showed myocarditis caused by HIV or cytomegalovirus. Grody et al,¹³ using sulfur 35-labeled RNA probes encompassing the entire HIV genome, found HIV nucleic acid sequences in cardiac tissue sections from six of 22 patients who died of AIDS.

The patient in this case lacked any apparent etiolog-

ic factors: he had a normal eosinophil count and absence of previous residence in a tropical area.

Clinical Presentation

The onset of EMF is usually insidious but progressive.¹⁴ Patients with right-sided involvement present with increased jugular venous pressure, a prominent V-wave, and rapid Y-wave descent. The right atrium is usually dilated. Hepatomegaly, ascites, and peripheral edema are common.¹⁵ A worse prognosis is seen in patients presenting with right-sided failure.¹⁶

Sudden death and syncopal episodes are not common in EMF compared with other causes of restrictive cardiomyopathy (eg, hypertrophic obstructive cardiomyopathy). However, atrial fibrillation may occur and is more frequent in patients with right ventricular disease.¹⁷ EMF may affect left, right, or both ventricles with extensive dense fibrous thickening of the apex, which may diminish ventricle size. Pulmonary congestion is common if the left side of the heart is involved. Fibrosis may extend up to the inflow portion of the ventricle and may involve papillary muscles, chordae tendineae and atrioventricular valves,¹⁸ leading to mitral or tricuspid insufficiency, stenosis, or both.¹⁹

Diagnosis

Echocardiography is the diagnostic test that reveals characteristic findings of EMF.²⁰ The patient in this case was diagnosed with EMF via two-dimensional echocardiography. Echocardiography shows apical obliteration of one or both ventricles by echogenic material, suggestive of fibrosis or thrombosis, causing small ventricles. In some cases, the right ventricle is the chamber primarily involved.²¹ With massive fibrosis, the right ventricle is virtually nonfunctioning and acts as a passive conduit. The systolic function of the ventricles is preserved. Because of the abnormal ventricular filling, the atria are almost always dilated in this disorder.²²

Endomyocardial biopsy may be helpful in diagnosis; however, because of the risk of dislodging a mural thrombus and subsequent embolization, endomyocardial biopsy is not routinely recommended. Moreover, the disease is often focal, and biopsy may miss the pathologic lesion.²³

Treatment

Currently, no effective treatment for EMF exists, and the prognosis for patients with advanced disease is poor.^{20,21} Patients have increasing right- or left-sided heart failure, and digitalis glycosides and diuretics are not particularly helpful. Surgery to excise the fibrotic endocardium with valve replacement, if required,

(continued on page 50)

(from page 48)

offers symptomatic improvement and is the treatment of choice in advanced disease.²³⁻²⁶

Prognosis

The prognosis is poor in advanced disease (35% to 50% of cases have a 2-year mortality).¹⁶ Roberts et al²⁷ reported that 95% of a group of patients died within 2 years of symptom onset. In a study by Shaper et al²⁸ of 356 patients from Uganda, Africa, 44% of patients with EMF died less than 1 year after the onset of symptoms and an additional 40% died 1 to 3 years after onset.

SUMMARY

HIV may infect heart muscle fibers and cause myocarditis, which usually leads to dilated cardiomyopathy. Restrictive cardiomyopathy in the form of EMF is uncommon. The patient in this case demonstrated such a finding. The pathophysiology of this phenomenon is unclear; however, inflammatory myocarditis may cause fibrosis, a theory which needs further investigation. Echocardiography is diagnostic of this disease. EMF presents with diastolic dysfunction of the ventricles. This disease has a poor prognosis and no effective treatment.

HP

REFERENCES

1. Valiathan MS: Endomyocardial fibrosis. *Natl Med J India* 1993;6:212-216.
2. Kaul S, Fishbein MC, Siegel RJ: Cardiac manifestations of acquired immune deficiency syndrome: a 1991 update. *Am Heart J* 1991;122:535-544.
3. Herskowitz A: Cardiomyopathy and other symptomatic heart diseases associated with HIV infection. *Curr Opin Cardiol* 1996;11:325-331.
4. Kutty VR, Abraham S, Kartha CC: Geographical distribution of endomyocardial fibrosis in south Kerala. *Int J Epidemiol* 1996;25:1202-1207.
5. Valiathan SM, Kartha CC: Endomyocardial fibrosis: the possible connection with myocardial levels of magnesium and cerium. *Int J Cardiol* 1990;28:1-5.
6. Shaper AG: What's new in endomyocardial fibrosis? *Lancet* 1993;342:255-256.
7. Mady C, Barretto AC, de Oliveira SA, et al: Evolution of the endocardial fibrotic process in endomyocardial fibrosis. *Am J Cardiol* 1991;68:402-403.
8. Oakley CM, Oslon EG: Eosinophilia and heart disease [editorial]. *Br Heart J* 1977;39:233-237.
9. Fauci AS, Harley JB, Roberts WC, et al: NIH conference. The idiopathic hypereosinophilic syndrome: clinical, pathophysiologic, and therapeutic considerations. *Ann Intern Med* 1982;97:78-92.
10. Olsen EG, Spry CJ: Relation between eosinophilia and endomyocardial disease. *Prog Cardiovasc Dis* 1985;27:241-254.
11. Tai PC, Ackerman SJ, Spry CJ, et al: Deposits of eosinophil granule proteins in cardiac tissues of patients with eosinophilic endomyocardial disease. *Lancet* 1987;1:643-647.
12. Herskowitz A, Wu TC, Willoughby SB, et al: Myocarditis and cardiotropic viral infection associated with severe left ventricular dysfunction in late-stage infection with human immunodeficiency virus. *J Am Coll Cardiol* 1994;24:1025-1032.
13. Grody WW, Cheng L, Lewis W: Infection of the heart by the human immunodeficiency virus. *Am J Cardiol* 1990;66:203-206.
14. Spyrou N, Foale R: Restrictive cardiomyopathies. *Curr Opin Cardiol* 1994;9:344-348.
15. Ribeiro PA, Muthusamy R, Duran CM: Right-sided endomyocardial fibrosis with recurrent pulmonary emboli leading to irreversible pulmonary hypertension. *Br Heart J* 1992;68:326-329.
16. Gupta PN, Valiathan MS, Balakrishnan KG, et al: Clinical course of endomyocardial fibrosis. *Br Heart J* 1989;62:450-454.
17. Fawzy ME, Ziady G, Halim M, et al: Endomyocardial fibrosis: report of eight cases. *J Am Coll Cardiol* 1985;5:983-988.
18. D'Silva SA, Kohli A, Dalvi BV, Kale PA: MRI in right ventricular endomyocardial fibrosis. *Am Heart J* 1992;123:1390-1392.
19. Barretto AC, da Luz PL, de Oliveira SA, et al: Determinants of survival in endomyocardial fibrosis. *Circulation* 1989;80:1177-1182.
20. Feigenbaum H: *Echocardiography*, 5th ed. Philadelphia: Lea & Febiger, 1994:535-536.
21. Acquatella H, Schiller NB, Puigbo JJ, et al: Value of two-dimensional echocardiography in endomyocardial disease with and without eosinophilia: a clinical and pathological study. *Circulation* 1983;67:1219-1226.
22. Presti C, Ryan T, Armstrong WF: Two-dimensional and Doppler echocardiographic findings in hypereosinophilic syndrome. *Am Heart J* 1987;114:172-175.
23. de Oliveira SA, Pereira Barretto AC, Mady C, et al: Surgical treatment of endomyocardial fibrosis: a new approach. *J Am Coll Cardiol* 1990;16:1246-1251.
24. Mady C, Barretto AC, Mesquita ET, et al: Maximal functional capacity in patients with endomyocardial fibrosis. *Eur Heart J* 1993;14:240-242.
25. Mady C, Pereira Barretto AC, de Oliveira SA, et al: Effectiveness of operative and nonoperative therapy in endomyocardial fibrosis. *Am J Cardiol* 1989;63:1281-1282.
26. Boustany CW Jr, Murphy GW, Hicks GL Jr: Mitral valve replacement in idiopathic hypereosinophilic syndrome. *Ann Thorac Surg* 1991;51:1007-1009.
27. Roberts WC, Liegler DG, Carbone PP: Endomyocardial disease and eosinophilia: a clinical and pathologic spectrum. *Am J Med* 1969;46:28-42.
28. Shaper AG, Hutt MS, Coles RM: Necropsy study of endomyocardial fibrosis and rheumatic heart disease in Uganda: 1950-1965. *Br Heart J* 1968;30:391-401.